

# Prefrontal Cortex in Humans and Apes: A Comparative Study of Area 10

Katerina Semendeferi,<sup>1\*</sup> Este Armstrong,<sup>2</sup> Axel Schleicher,<sup>3</sup> Karl Zilles,<sup>3</sup> and Gary W. Van Hoesen<sup>4</sup>

<sup>1</sup>*Department of Anthropology, University of California, San Diego, La Jolla, California 92093*

<sup>2</sup>*Department of Cellular Pathology, Armed Forces Institute of Pathology, Washington, DC 20306*

<sup>3</sup>*C. and O. Vogt Institute for Brain Research, Heinrich-Heine University Düsseldorf, Düsseldorf D-40225, Germany*

<sup>4</sup>*Departments of Anatomy and Cell Biology and Neurology, University of Iowa, Iowa City, Iowa 52242*

**KEY WORDS** frontal pole; brain evolution; cytoarchitecture; brain mapping; stereology; hominoid; hominid

**ABSTRACT** Area 10 is one of the cortical areas of the frontal lobe involved in higher cognitive functions such as the undertaking of initiatives and the planning of future actions. It is known to form the frontal pole of the macaque and human brain, but its presence and organization in the great and lesser apes remain unclear. It is here documented that area 10 also forms the frontal pole of chimpanzee, bonobo, orangutan, and gibbon brains. Imaging techniques and stereological tools are used to characterize this area across species and provide preliminary estimates of its absolute and relative size.

Area 10 has similar cytoarchitectonic features in the hominoid brain, but aspects of its organization vary

slightly across species, including the relative width of its cortical layers and the space available for connections. The cortex forming the frontal pole of the gorilla appears highly specialized, while area 10 in the gibbon occupies only the orbital sector of the frontal pole. Area 10 in the human brain is larger relative to the rest of the brain than it is in the apes, and its supragranular layers have more space available for connections with other higher-order association areas. This suggests that the neural substrates supporting cognitive functions associated with this part of the cortex enlarged and became specialized during hominid evolution. *Am J Phys Anthropol* 114:224–241, 2001. © 2001 Wiley-Liss, Inc.

The prefrontal cortex is located rostral to the motor and premotor cortices. It is also called the frontal association cortex or the frontal granular cortex, referring to its functional and structural attributes, respectively. Like the rest of the cortex, it has been subdivided qualitatively into smaller architectonic regions on the basis of their distinct neuronal organization, such as the number and size of the cortical layers, the size, shape, and density of the neurons, and the degree of axon myelination. In addition, support for this more refined cortical parcellation comes from the distinct connections of each cortical area with the various subdivisions of the mediodorsal nucleus of the thalamus and other cortical and subcortical structures (like the temporal and parietal lobes, the hypothalamus, the amygdala, and the hippocampal formation).

In humans, lesions on the dorsolateral portion of the prefrontal cortex, including area 10, are associated with impairment in higher-cognitive abilities that facilitate extraction of meaning from ongoing experiences, the organization of mental contents that control creative thinking and language, and the artistic expression and planning of future actions (Damasio, 1985). Frontal lobe impairment produces the delayed response deficit that has been related to the lack of initiative or, in other words, the impairment of “interest and hence sustained attention and

initiative” (Sanides, 1964; see also Harlow et al., 1964; Rosvold et al., 1964). Area 10 is located in the frontal pole and is one of the areas involved with the planning of future actions, the undertaking of initiatives, and to some extent working memory and attention (Okuda et al., 1998; Lepage et al., 2000; Daffner et al., 2000).

The primate prefrontal cortex, including the frontal pole, has been the focus of a host of studies for the past century. In recent attempts to map the primate cortex, the qualitative evaluation has been complemented by more objective approaches, including the quantification of different areas (Rajkowska and Goldman-Rakic, 1995a,b; Hof et al., 1995; Semendeferi et al., 1998). Although monkey (mostly macaque) cytoarchitecture has been described by many researchers (e.g., Brodmann, 1909; Walker, 1940; Preuss and Goldman-Rakic, 1991; Carmichael and

Grant sponsor: Leakey Foundation; Grant number: QM54; Grant sponsor: Wenner-Gren Foundation; Grant number: 5553; Grant sponsor: National Science Foundation; Grant number: G13.

\*Correspondence to: Katerina Semendeferi, Department of Anthropology, University of California, San Diego, 9500 Gilman Drive, La Jolla, CA 92093-0532. E-mail: ksemende@ucsd.edu

Received 1 June 1999; accepted 21 November 2000.

Price, 1994), studies of the prefrontal cortex of apes are scarce.

Here we address the issue of the homology of area 10 on the basis of quantifiable cytoarchitectonic criteria. We estimate the overall volume of the area in hominoids, and we explore aspects of its organization, including the relative size of cortical layers, numbers of neurons, and neuropil space. On the basis of the comparative information, we reconstruct aspects of the evolution of area 10 in hominoid and hominid brains.

## MATERIALS AND METHODS

### Materials

Subjects of all extant hominoids (humans, chimpanzees, bonobos, gorillas, orangutans, and gibbons) were studied. One Old World monkey, the rhesus monkey, was also included as an outgroup comparison. Two to ten hemispheres per species were included in the qualitative part of the investigation, and one hemisphere (right) per species was quantified. The quantified specimens were selected on the basis of the quality of staining and of the consistency in the fixation protocol and processing procedures. Included are adult individuals of both sexes, except for the bonobo, which is represented by a 2-year-old subject (exact age is not known for apes; the human was 75 years old). None of the subjects died of neurological disease. All quantified specimens were emerged in 4% formalin within a few hours after the natural death of the subject, and were processed and stained in the same manner (Semendeferi et al., 1998). They were cut at 20  $\mu\text{m}$ , and every tenth or fifteenth section was stained with a modification of the Gallyas silver stain for neuronal perikarya (Gallyas, 1971; Merker, 1983).

### Methods

**Estimates of volumes.** The volume of the cortical gray of area 10 was obtained from histological sections with the use of stereological techniques that estimate unbiased volume of brain structures and other irregularly shaped objects with a precision better than 5% (Gundersen et al., 1988a,b).

**Grey-level index.** The grey-level index (GLI) method detects the percent-area of stained perikarya vs. neuropil, and demonstrates interareal and interlaminar differences in these densities across species (Schleicher and Zilles, 1989; Semendeferi et al., 1998). GLI values are a summation of neuronal cell bodies, glial nuclei, and endothelial cell nuclei divided by the total space. Thus, the lower the GLI value, the more space there is for connections (Schlaug et al., 1993), including connections with other cortical and subcortical areas and intrinsic connections.

Selected locations, undistorted by cortical folding, were digitized. The resultant computer images were used to generate laminar profiles of cell distribution. The profiles primarily describe variation in neuronal volume density (glial and endothelial cell nuclei are

only a small portion of the total volume) throughout the cortical depth, starting at the pial surface and ending at the white/gray matter interface.

A characteristic profile for each species was derived by standardizing individual profiles to the same relative width, and then averaging the GLIs. The x-axis represents the relative cortical depth of the area, and the y-axis represents the GLI value which shows the percent-area covered by cell bodies vs. neuropil space (for more details see Semendeferi et al., 1998). Subsequently, mean GLI values were calculated for the entire profile, and for three groups of cortical layers whose boundaries could be identified reliably across species (supragranular layers II and III, layer IV, and infragranular layers V and VI).

**Relative size of cortical layers.** The above profiles were used in the following manner to help determine the thickness of the cortical layers and the mean GLI values within each layer. Area 10 in all seven species was measured in the same manner. Microscopic sections of the cortex were projected through a camera lucida over each profile. By this means, profile curves were directly superimposed onto the image of the histological section, enabling the maxima and minima of the profile to be matched with the cytoarchitectonically and qualitatively defined layers.

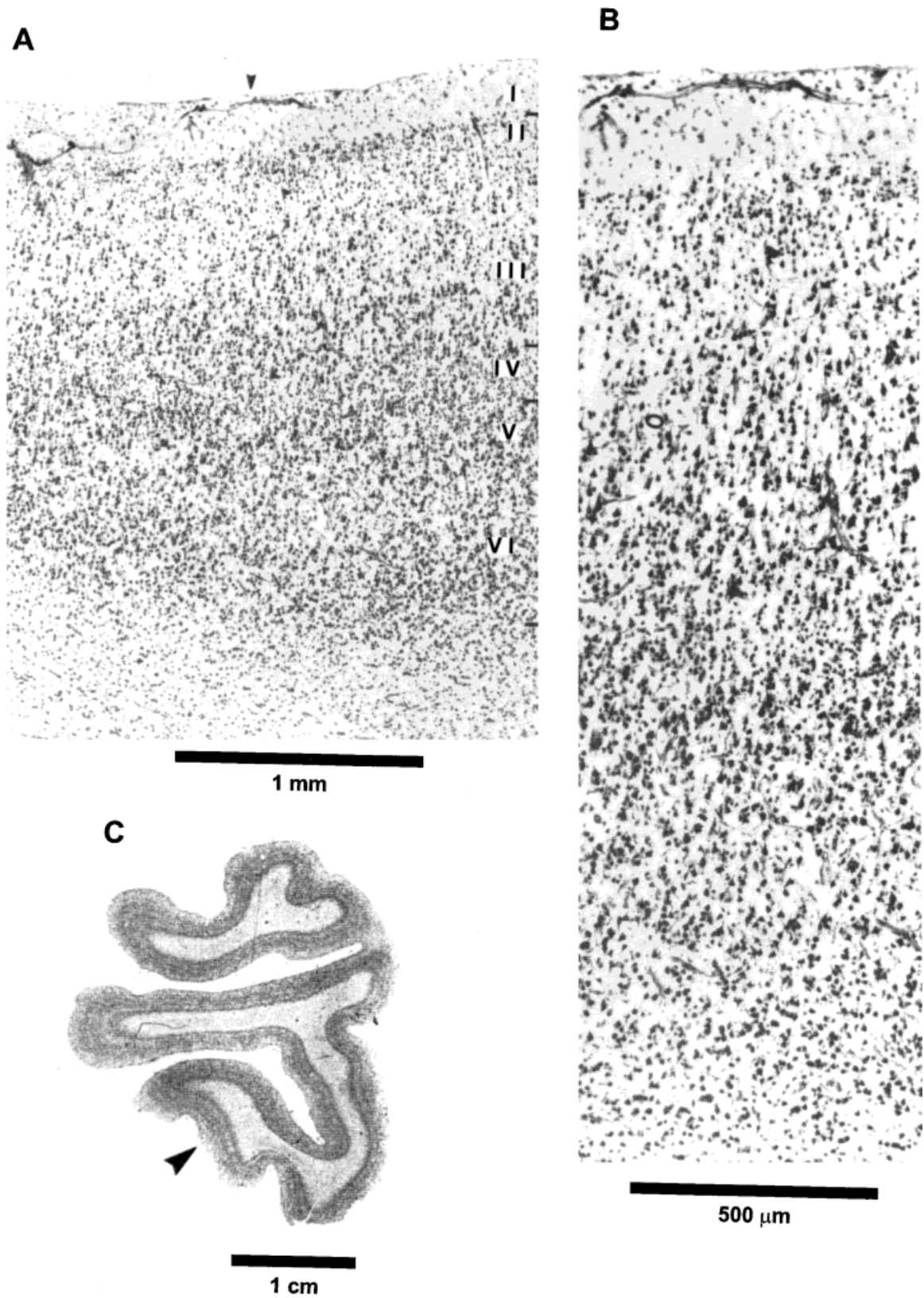
**Neuronal counts.** The total number of neurons was determined for area 10 by applying the optical fractionator, a modern stereological method for obtaining estimates of total numbers of neurons in a cortical area (West and Gundersen, 1990; West et al., 1991; Hyman et al., 1998). Neurons were identified and counted in a light microscope, using a 60 $\times$ -oil immersion objective with a numerical aperture of 1.4 (Semendeferi et al., 1998).

## RESULTS

### Cytoarchitecture of area 10

The results of the cytoarchitectonic evaluation of area 10 are based on a qualitative description. The size of cortical layers, the stain intensity, and the size of cells are described in relation to each other (e.g., when a cortical layer is identified as "thin," this means that it is thin in relation to the size of the other layers). A quantitative investigation is presented later.

**Human.** The frontal polar cortex of nine human hemispheres (from five brains) is investigated in serial sections stained with the Nissl and Gallyas methods (Fig. 1). In all specimens, the cortex forming the frontal pole has a remarkably homogeneous appearance (there is no exaggeration in the appearance of any of the layers). Six cortical layers are easily distinguished. In comparison to the rest of the layers, layer I is thin to medium in width. Layer II is thin and, although not prominent, it is easily iden-



**Fig. 1.** Photomicrographs of human area 10. **A:** Cortical layers I–VI. Scale bar = 1 mm. Arrow marks location of magnified histological section shown in **B** (scale bar = 500  $\mu$ m) **C:** Coronal section through the frontal pole. Arrow marks presence of area 10.

TABLE 1. Cytoarchitectonic features of area 10<sup>1</sup>

	Human	Chimpanzee	Bonobo	Gorilla <sup>2</sup>	Orangutan	Gibbon	Macaque
Layer I							
Layer size <sup>3</sup>	TH/M	M/W	M	TH	TH/M	TH/M	M
Layer II							
Layer size	TH	M	TH	M	TH	TH/M	TH
Cells	S	S	S	S	S	S	S
Staining	M/DA	DA	M	DA	DA	DA	NR
Layer III							
Layer size	W	W	W	W	W	W	W
Cells	S/PYR	S/PYR	PYR	L/PYR	L/PYR	PYR	M-L/PYR
Staining	M/DA	DA	DA	M/DA	DA	DA	NR
Layer IV							
Layer size	TH	TH	TH	TH	TH	TH	TH
Cells	S	S	S	S	S	S	S
Staining	PA/M	M	PA/M	PA	M	M	NR
Layer V							
Layer size	W	NR	NR	PRO/M	NR	PRO	M/W
Cells	L/PYR	PRO/PYR	PYR	L/PYR	M/PYR	L/PYR	L
Staining	PA	NR	DA	DA	DA	DA	NR
Layer VI							
Layer size	NR	PRO	NR	PRO/M	M	NR	M
Cells	L	L	L	L	L	L	L
Staining	DA	DA	DA	DA	NR	DA + PA	NR

<sup>1</sup> TH, thin; M, medium; W, wide; S, small; L, large; PA, pale; DA, dark; PRO, prominent; PYR, pyramidal; NR, not recorded.

<sup>2</sup> In this species, the description refers to the cortex of the frontal pole.

<sup>3</sup> The size of each layer is described in relation to the size of the other layers. For a quantitative description, see Table 4.

tifiable. It includes small granular and pyramidal cells that have a medium to dark staining. Layer III is the widest layer in the frontal pole, and its cells have a small, but gradual change in size; the pyramids close to layer II are smaller than those close to layer IV, and have a medium to dark staining. Layer IV is thin, but continuous with pale to medium stained granular and pyramidal cells. Its borders with layers III and V are clear and regular. Layer V is wide and includes large pyramids, though their sizes are only minimally larger than those of the pyramidal cells of layer III. Two sublayers, Va and Vb, are seen clearly. The density of cells in Vb is less than that of Va, and many of the neurons have a pale staining. Layer VI includes dark pyramidal and fusiform cells. Its borders with layer V and the white matter are regular (Table 1).

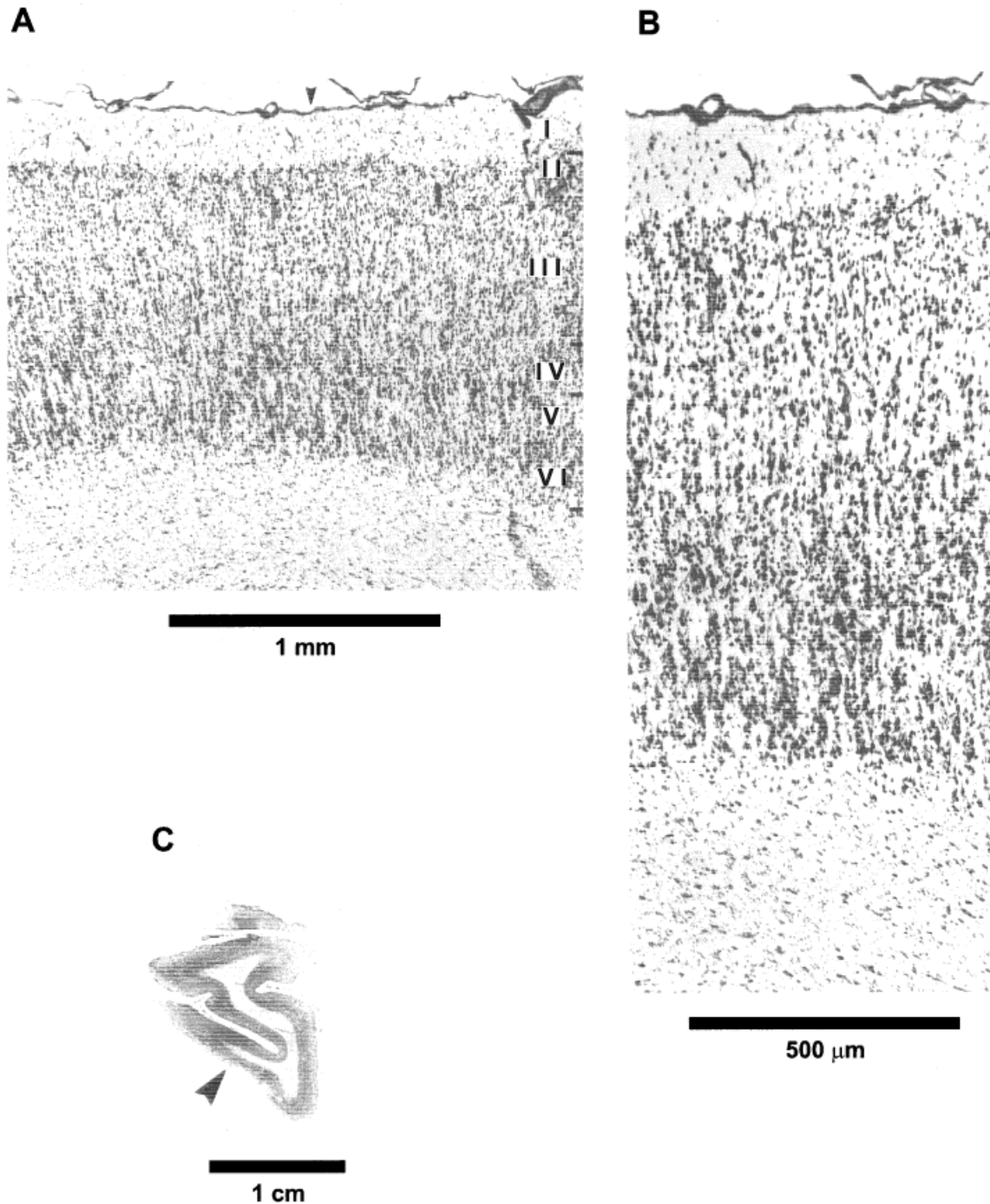
Caudally, area 10 borders with other cortical areas on the dorsolateral, mesial, and orbital surfaces. The cortex of the superior frontal gyrus (on the dorsomesial and dorsolateral surfaces), which constitutes Brodmann's area 9, is characterized by a more distinct layer Vb that has a much lower cell-packing density than Va or VI. Also, layer II becomes particularly prominent. It has a higher cell-packing density than layer II in area 10, and the cells are darkly stained. On the orbital surface, Brodmann's area 11 that neighbors area 10 includes a thinner layer IV. Layers Va and VIb become more prominent in this cortical area, as does layer II.

**Chimpanzee.** The frontal pole of the chimpanzee is investigated in six hemispheres (three brains). The cortex in this species resembles the human frontal pole. When compared to the rest of the layers, layer I has a medium to thick width. Layer II is easily distinguishable and is of medium size. Its

cells are small and darkly stained. Layer III is very wide, its cells have a homogeneous distribution, and a slight size gradient is evident as one approaches layer IV. The pyramids are darkly stained. Layer IV is clearly evident, but thin, and includes small cells with medium staining. Its borders with layers III and V are easily seen. Layer Va includes prominent pyramids only slightly larger than those of layer III, and layer Vb has an unclear border with layer VI. Layer VI includes large cells that are darkly stained. Layers Va and VIa are prominent, while Vb and VIb have a decreased density of cells (Fig. 2).

The neighboring cortical area located in the caudal parts of the frontomarginal sulcus (area FDI? of Bailey et al., 1950) has a much smaller overall thickness, a prominent layer II, and a layer IIIa that has a decreased cell-packing density. Layer IV is not clear, although layers V and VI are very much like those observed in area 10. Even further caudally, the cortex on the dorsolateral surface (area FB?) includes pyramids in layer Va that become considerably larger. On the dorsomesial surface the neighboring cortex has a layer IV that becomes wider, while the pyramids in layer V are much larger than those in layer III (area FC?). On the orbital surface, layer IV becomes less regular (area FG?). These features are similar to those that characterize the neighboring-to-area-10 cortical areas in the human brain.

**Bonobo.** Two hemispheres (one brain) of the bonobo are included in this investigation of the frontal pole. In this species, the cortex of the frontal pole is very homogeneous and includes a prominent layer Va and VI, and a sharp border with the white matter. Layer I is medium in width and layer II is distinguishable but thin when compared to the rest



**Fig. 2.** Photomicrographs of chimpanzee area 10. Magnifications and arrows are as in Figure 1.

of the layers. Its cells have a medium stain intensity. Layer III has a homogeneous appearance in cell-packing density and in cell size. It is a wide layer, with cells that are darkly stained. Layer IV is thin but clearly present and contains pale to medium-stained cells. Layer V has a clear border with IV. It includes densely packed and darkly stained pyramids in Va, but a less densely packed Vb. In layer VI, cells are dark and the gray matter-white matter border is sharp (Fig. 3).

The neighboring cortical areas on the mesial and dorsal surfaces have an extremely thin layer IV and very prominent pyramids in IIIb and Va. In addition, on the mesial surface, layer II becomes prominent and the borders of layer IV become irregular at locations. Unlike those of the human and the chimpanzee, the frontal cortices of the bonobo and the rest of the hominoids have not been mapped before, and thus reference to neighboring areas cannot be made with specific numeric or alphabetic designa-

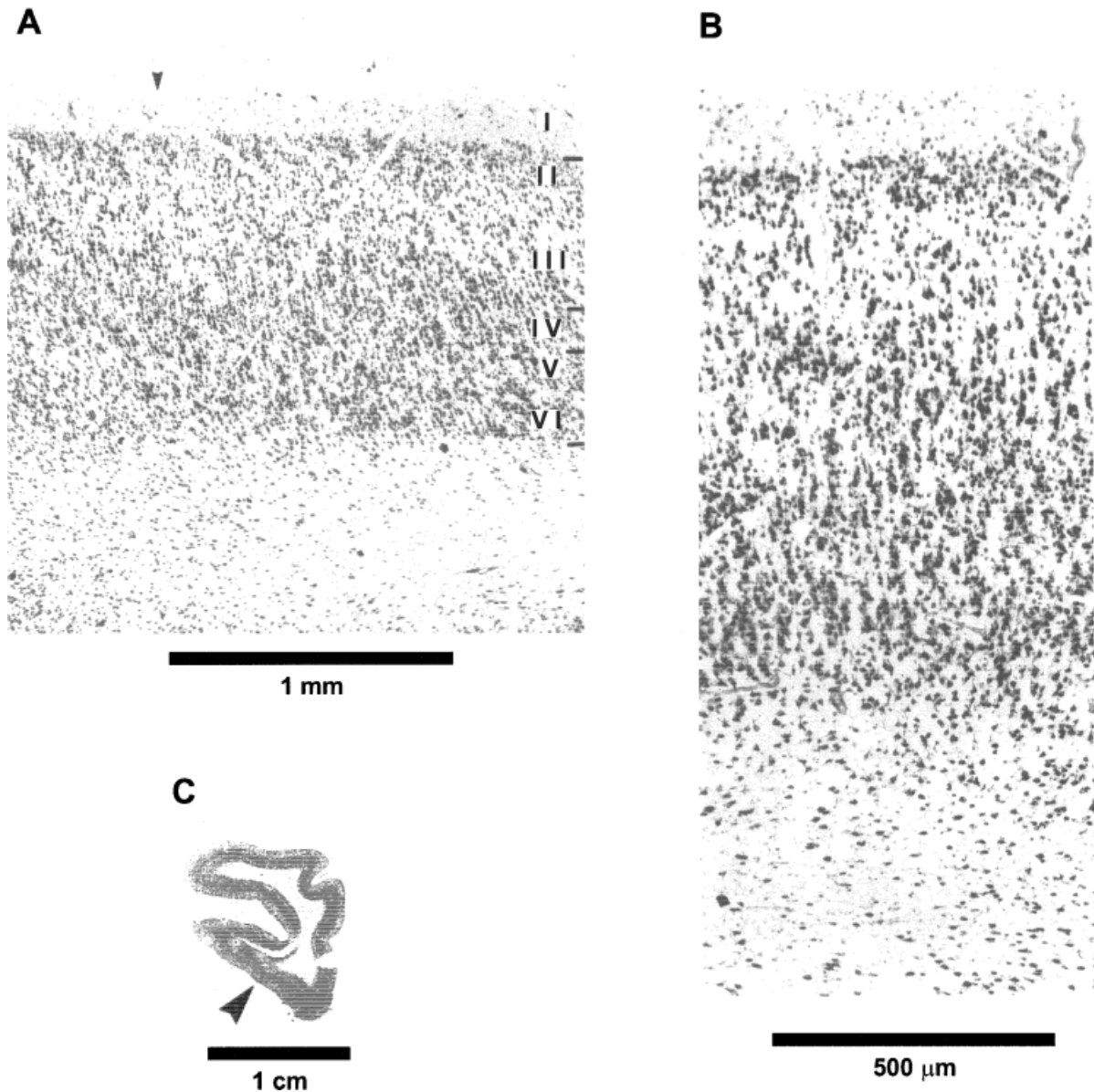


Fig. 3. Photomicrographs of bonobo area 10. Magnifications and arrows are as in Figure 1.

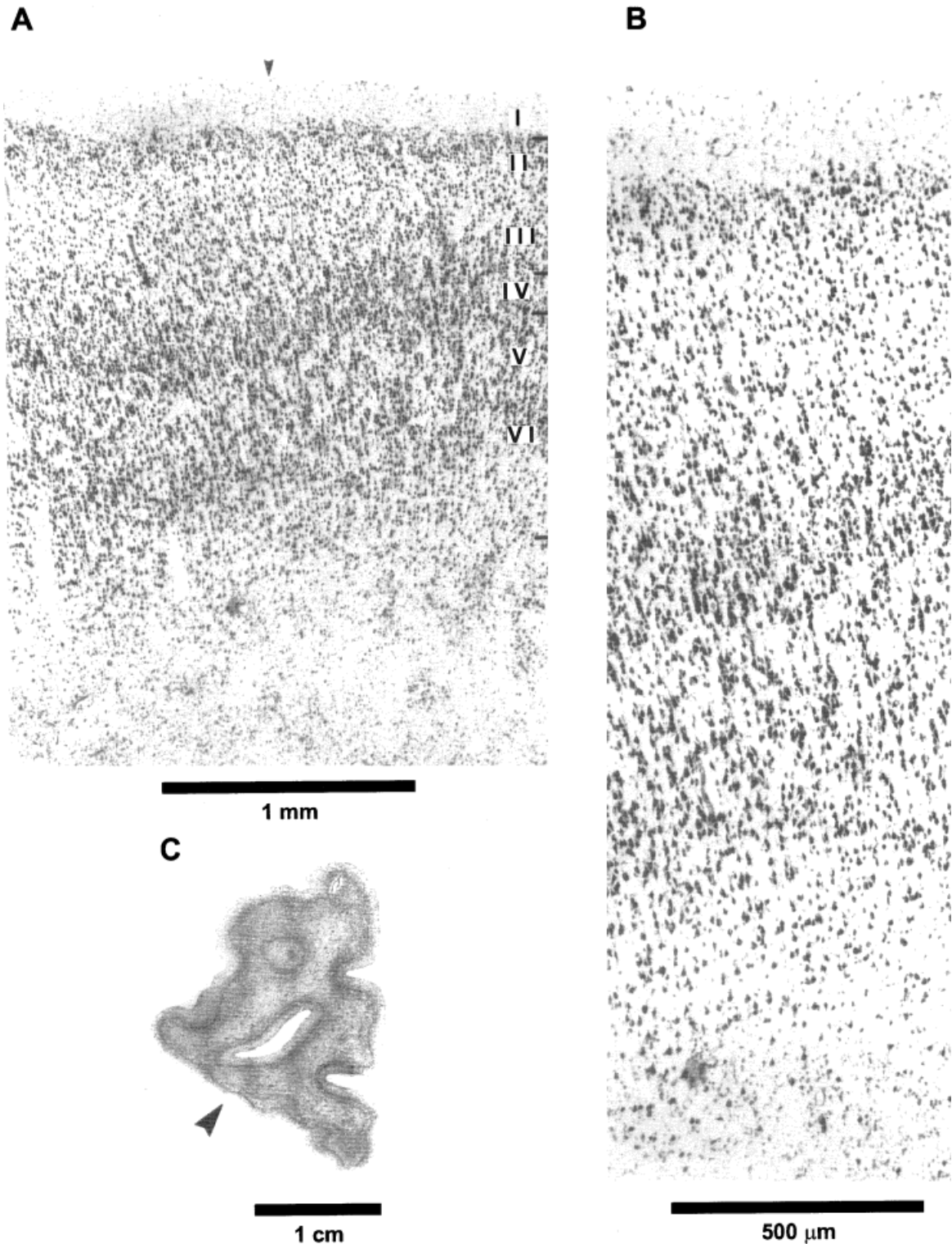
tions. The distinction is based on the cytoarchitectonic features presented here, and there is an obvious need for an extensive study of all cortical areas of the prefrontal cortex.

**Gorilla.** The frontal pole of the gorilla is investigated in two hemispheres (one brain). The frontal pole in this ape has a distinct appearance. Layers II and Va are very prominent, and because of this, the cortex as a whole does not have the homogeneous appearance that it has in the other hominoid brains. Layer I is narrow, while layer II has a medium width; it is prominent and its cells are dark. Layer III is wide, some of its pyramidal cells have a slight size gradient with a medium staining intensity, and some are dark, large pyramids. Layer IV is very thin and its cells are pale, while layer V is very promi-

nent with large, dark pyramids. Layer VI includes darkly stained cells (Fig. 4).

The cortical area that forms the frontal pole differs from the surrounding areas in a variety of features. The neighboring cortical area on the mesial surface has pyramids in layer IIIb that are larger and more prominent. The cortex appears to have three darker bands (layers IIIb, Va, and II). On the orbital surface the cortex changes, having a very prominent layer Va and VIa, with larger and more darkly stained cells. Layer II remains very prominent as well.

Some, but not all, of the cortical features of the gorilla frontal pole resemble those of the rest of the hominoids. The prominence of layers II and Va is unique to this species and does not meet all the cytoarchitectonic criteria established in this study

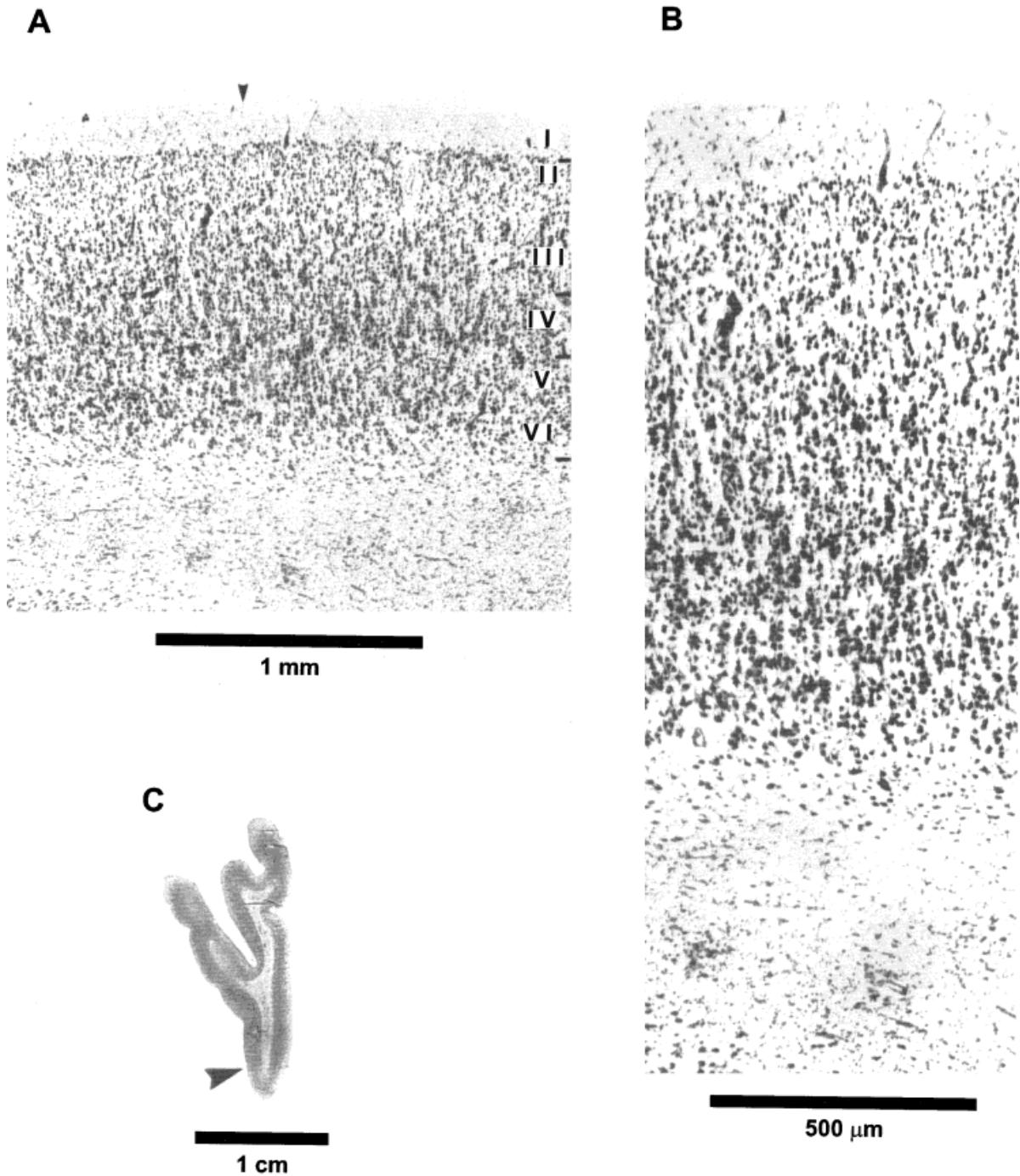


**Fig. 4.** Photomicrographs of gorilla frontal pole cortex. Magnifications and arrows are as in Figure 1.

for homology with area 10. Consequently, on the basis of the material included here, the homology of the cortex forming the frontal pole in the gorilla, and area 10 in the rest of the hominoids, is questionable. Examination of more specimens is imperative in

order to clarify this issue and test these preliminary findings.

**Orangutan.** Three hemispheres (two brains) of the orangutan are included in the analysis of the



**Fig. 5.** Photomicrographs of orangutan area 10. Magnifications and arrows are as in Figure 1.

frontal pole. The cortex forming the frontal pole in this species has a homogeneous appearance, similar to that of the two chimpanzee species and the human.

Layer I is thin to medium in width, and layer II is very thin and includes dark cells. Layer III is homogeneous and wide, with large and dark pyramids that are larger closer to the borders with layer IV, and almost equal in size to those in layer V. Layer IV is thin, has clear borders with III and V, and has a

medium staining intensity in its small cells. Layer Vb has a slightly lower cell-packing density than Va, whose pyramids are medium sized and darkly stained. Layer VI is medium in size and includes large pyramids. It has clear borders with the white matter (Fig. 5).

Area 10 in the orangutan is surrounded by other cortical areas that are located in more caudal parts of the frontomarginal sulcus and on the mesial and orbital surfaces. Specifically, in more caudal sec-



tions, the cortex within the frontomarginal sulcus changes slightly, and layer II becomes prominent (very much as in the chimpanzee brain). Also, the cortex on the mesial surface stands out by having more pronounced layers II, Va, and VIa. On the orbital surface, the cortex neighboring area 10 has a wide layer IV, and the pyramids in IIIa are larger than the ones in area 10 or in its own layer V; layer IIIb has reduced cell-packing density.

**Gibbon.** Two hemispheres (one brain) of the gibbon are included in the investigation of area 10. Unlike the other hominoid specimens, the cortex that forms the gibbon frontal pole is composed of two cortical areas: one dorsal to the principal sulcus (sulcus rectus), and the other orbital to the principal sulcus. The dorsally located cortical area has more pronounced layers Va and II, an appearance similar to that of the gorilla frontal pole. The orbitally located cortical area is more homogeneous and has structural features similar to those of the human, chimpanzee, bonobo, and orangutan area 10. Only the orbital sector of the frontal pole is identified here as area 10 (it meets the criteria established for homology with area 10 across species). The dorsal part of the frontal pole forms a different cortical area (Brodmann's area 9?) that needs to be further investigated.

Area 10 in the gibbon is a thin, homogeneous cortex. Layer I is thin to medium in width, and layer II is thin to medium and slightly more prominent, with dark cells. Layer III is wide and homogeneous, includes dark pyramids, and has a reduced cell-packing density in IIIa. Layer IV is clearly present, having irregular borders and medium-stained cell intensity. Layer Va is slightly more prominent, and its darkly stained pyramids are slightly larger than those in III. The cell-packing density is reduced in Vb. Layer VI is homogeneous, including large cells which are either darkly stained or pale. The border between layer VI and the white matter is sharp (Fig. 6).

Further caudally on the orbital surface, the cortical area that neighbors area 10 has more irregular borders, particularly around layer IV. Layer IIIa has reduced cell-packing density at some locations, and the pyramids in Va are much larger. The cortex within the principal sulcus includes a wide layer II, a denser layer III, and a sharp border between layer VI and the white matter. Whether these neighboring areas are areas 46 or 11 or some other areas remains to be investigated.

**Macaque.** The frontal pole of nine hemispheres (five brains) of the macaque is examined. As a whole, the cortex in the frontal pole includes a medium-size layer I. Layer II is very thin, and its borders with layer III are hard to differentiate. The cells are small, and their density is high in layer II. Layer III is wide and includes medium to large pyramidal cells. The cell-packing density in this layer is medium; there are no clear sublayers (IIIa or IIIb), but

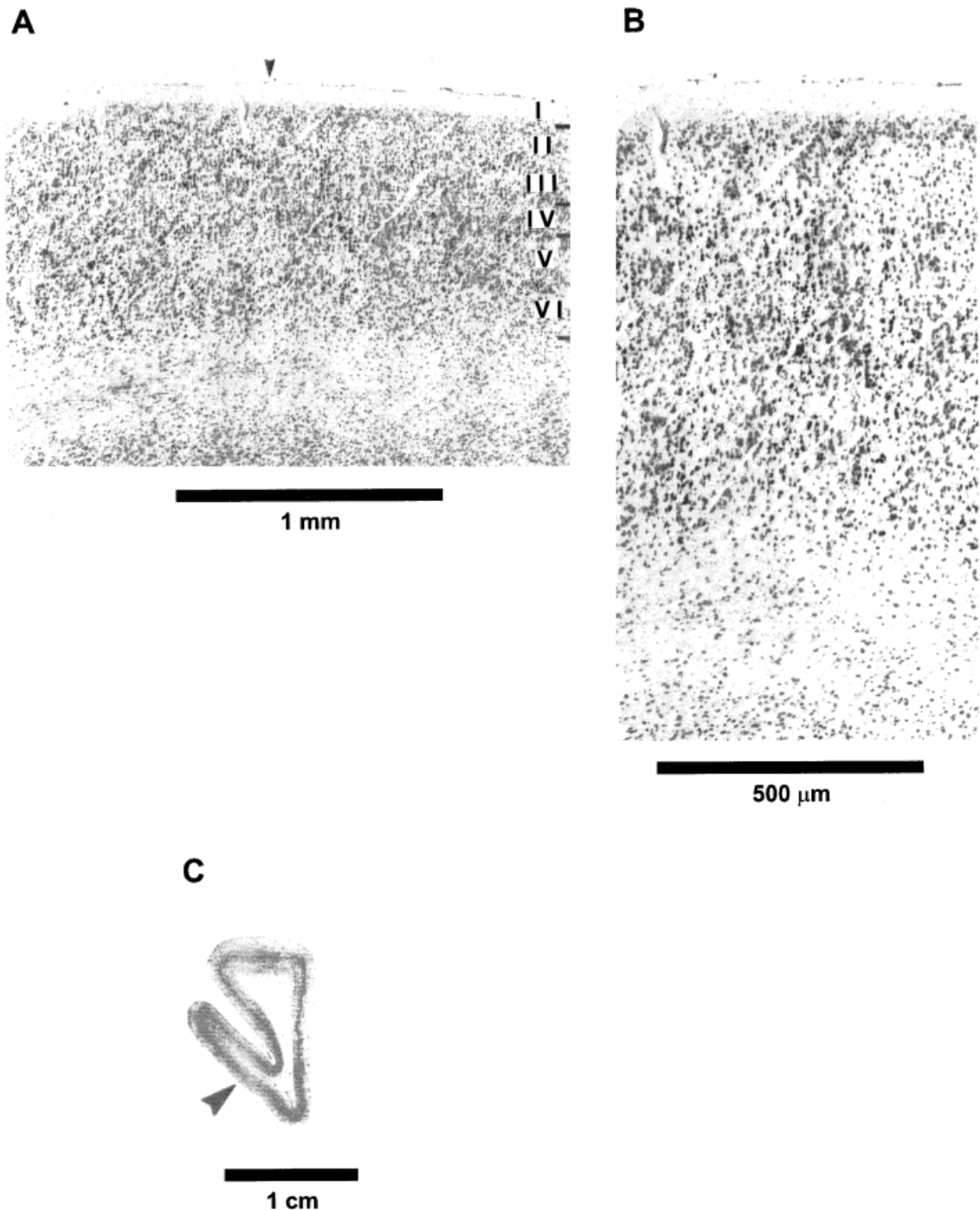
there is a slight size gradient among the pyramidal cells. Layer IV is thin and includes small cells that occur in high density. In the dorsal part of the frontal pole, layer V is medium to thick in width and includes large cells in high density. Layer Vb is very thin and has considerably less cell density than in Va. Layer VI throughout the frontal pole is medium in size and includes large cells. This layer has a medium cell-packing density.

It should be noted that there are some differences in the structural features within the frontal pole of the macaque that suggest a subdivision of this cortex into a dorsomesial and orbitolateral component. The dorsal part of the frontal pole has a prominent layer Va, while the orbital sector has a more homogeneous overall appearance and a less pronounced layer V. In the orbital part of the frontal pole, layer Va is less prominent, and the difference between Va and Vb in cell-packing density and size of cells is smaller. According to the cytoarchitectonic criteria used in this study, the cortex of the orbital sector of the macaque is more homogeneous and resembles closely area 10 in the gibbon, which likewise occupies the orbital sector of the frontal pole.

In summary, the cytoarchitectonic evaluation presented above suggests the following picture regarding the presence of area 10 in the primate brains examined. In macaques, area 10 has two components, one on the dorsal part of the frontal pole and the other on the orbital part. The orbital sector of area 10 in the macaque shares similar structural features with area 10 in the gibbon brain. In the gibbon, area 10 occupies only the orbital sector of the frontal pole and is homologous with area 10 in human, bonobo, chimpanzee, and orangutan brains. In these species, area 10 forms the entire frontal pole. The frontal pole of the gorilla brain examined here is distinct and resembles more closely the dorsal part of the frontal pole in the gibbon, a cortical area neighboring area 10 in that species. The homology of the cortical area that forms the frontal pole in the gorilla and area 10 as defined in the rest of the hominoids is questionable and needs further investigation.

#### Quantification of area 10

**Size.** Area 10 is larger by far in the human brain than in the other hominoids ( $14 \text{ cm}^3$  vs.  $2.8 \text{ cm}^3$  in the bonobo) (Table 2, Fig. 7). Even in relative terms, it is twice as large in the human brain as in any of the great apes. Area 10 of the human right hemisphere makes up 1.2% of the entire brain volume, and its size ranges between 0.46–0.74% of brain volume in the great apes (largest in the bonobo and smallest in the orangutan in both absolute and relative terms). We plotted the volume of area 10 against total brain volume (Fig. 8a), and we drew a best-fit regression line (least squares) through the nonhuman hominoid data. On the basis of this linear plot, the human expected value is  $7.65 \text{ cm}^3$ ; the observed value lies well above the regression line,



**Fig. 6.** Photomicrographs of gibbon area 10. Magnifications and arrows are as in Figure 1.

and is almost twice as large as expected ( $Y = 14.22 \text{ cm}^3$ ). When plotted in a log-log scale (least squares) (Fig. 8b), the human value appears to be as large as expected ( $Y = 1.13$  vs.  $1.15$ ). The small sample size does not allow for a conclusive allometric analysis of area 10. We suggest that both in absolute terms and relative to the rest of the brain, area 10 in humans is much larger than in apes; the use of more specimens will establish whether it is also allometrically enlarged.

**Grey-level index.** The GLI profiles record the variation in cell body density through the depth of the cortex. Peaks in the profile (increased GLI values) indicate that more space is occupied by cell bodies. In the human brain, the profile is unimodal and has relatively lower values in the supragranular layers (Fig. 9). The overall mean GLI value is the lowest among the primates (Table 3).

The distribution of values in the mean GLI profile of chimpanzee area 10 is very homogeneous. The

TABLE 2. Volumes of the brain and area 10 in all hominoids<sup>1</sup>

Species	Brain <sup>2</sup>	Area 10 <sup>3</sup>
Human	1,158,300	14,217.7
Chimpanzee	393,000	2,239.2
Bonobo	378,400	2,804.9
Gorilla <sup>4</sup>	362,900	1,942.5
Orangutan	356,200	1,611.1
Gibbon	88,800	203.5

<sup>1</sup> Volume estimates in mm<sup>3</sup>; included is the right hemisphere of one individual per species.

<sup>2</sup> Figures refer to total brain structure.

<sup>3</sup> Figures refer to area 10 of the right hemisphere.

<sup>4</sup> In this species, measurements for area 10 refer to the cortex of the frontal pole.

profile is unimodal, with a large plateau starting at layer II and ending at layer VIa. Slightly lower values are found within layer IIIb than in VIb. The mean value for this area is 17.52, a value considerably larger than that for the human. In the bonobo brain, area 10 is characterized by a bimodal mean GLI profile. The peaks in the profile are found within layers II and Va. A significantly lower value is part of layer III. The mean GLI value in the bonobo is 18.17, exceeding the GLI value of both the chimpanzee and human (Table 3). In contrast to the above two species, the infragranular layers have a lower mean GLI value (16.21) than the supragranular layers (18.95). Again, the granular layer has the highest value (21.60).

The gorilla frontal pole profile is very different from the profiles of the other species (Fig. 9). This profile has three large peaks and three areas with very low values. The peaks are found within layers II, IIIb, and V, while the lower values are part of layer IIIa, upper parts of Va, and VIb. The mean GLI value for the gorilla frontal pole is low (15.87), almost as low as in the human brain. The distinct appearance of the GLI profile only reinforces the conclusions drawn from qualitative observations and other quantitative measurements that suggest a different organization of the cortex of the gorilla frontal pole, at least in this specimen.

The orangutan area 10 profile is very homogeneous, much like that of the chimpanzee. The values form one large plateau that begins in layer II and ends in layer VI. A slightly lower value was observed for layer Vb, and no other major or minor peaks or lows are present. The mean GLI value of the orangutan area 10 is the highest in the great ape/human group. Unlike these other species, the infragranular and supragranular layers of the orangutan have similar values.

The gibbon area 10 profile is bimodal. Higher peaks are found in layers II and IV. The mean GLI value is similar to that of the orangutan and the macaque, as are the values for the infra- and supragranular layers. In the macaque, the mean GLI profile of area 10 has an overall homogeneous distribution of values, with several smaller peaks and lows along its length. Some of the peaks are seen in layers

II, III, V, and VI, while some of the lower values are part of III and Vb. The mean GLI value for the macaque is 20.34, which is the highest value of all species studied.

**Relative size of cortical layers.** Values for the relative width of the supragranular, granular, and infragranular layers were obtained (Table 4). In the human, layer I has a mean value of 11% of the total cortical depth, layers II and III make up 43% of the cortical thickness, and infragranular layers V and VI constitute 40%. Layer IV makes up 6% of the total depth. The chimpanzee and the bonobo have a similar distribution of values relative to the human brain and to each other.

In the gorilla, although layers I and IV have relative values similar to the other hominoids, the relationship between the size of the supragranular layers and the infragranular layers differs. The size of the infragranular layers is almost half the total thickness of the cortex of the frontal pole, while the size of layers II and III is reduced. With regard to the gibbon and the macaque, the values are similar, with the exception of layer IV, which is much wider in the gibbon brain (11% vs. 6% in the macaque).

**Neuronal numbers.** Area 10 in the right human hemisphere has an estimated 254.4 million neurons, while the great apes have less than one third of that amount (Table 5). Area 10 in the gibbon is much smaller in comparison to the larger hominoids, and has a total of only 8 million neurons. When it comes to density of neurons, however, the reverse relationship holds true: the human brain has the lowest density and the gibbon has the highest. Among the great apes, the orangutan has the highest density of neurons.

## DISCUSSION

The frontal pole and the surrounding cortices are examined in seven primate species in order to identify and delineate area 10. We evaluate qualitatively the structure of area 10 in two or more hemispheres per species; we also quantify features of area 10 in one hemisphere per species, which is processed and stained in a consistent manner. For purely logistical reasons (e.g., availability of tissue, condition of post-mortem material), a larger-scale comparison including multiple techniques and larger samples, although highly desirable, was not possible. For this reason, we closely considered descriptions of area 10 in macaques and humans given by other investigators who had studied the cortex of individual species in a noncomparative way, using larger samples and multiple techniques.

The main issues in this study are: how do we define area 10, and is this area present and homologous in macaques, humans, and the rest of the hominoids? Are our comparative observations in agreement with other studies that focused on only one species, using, in some cases, larger samples and

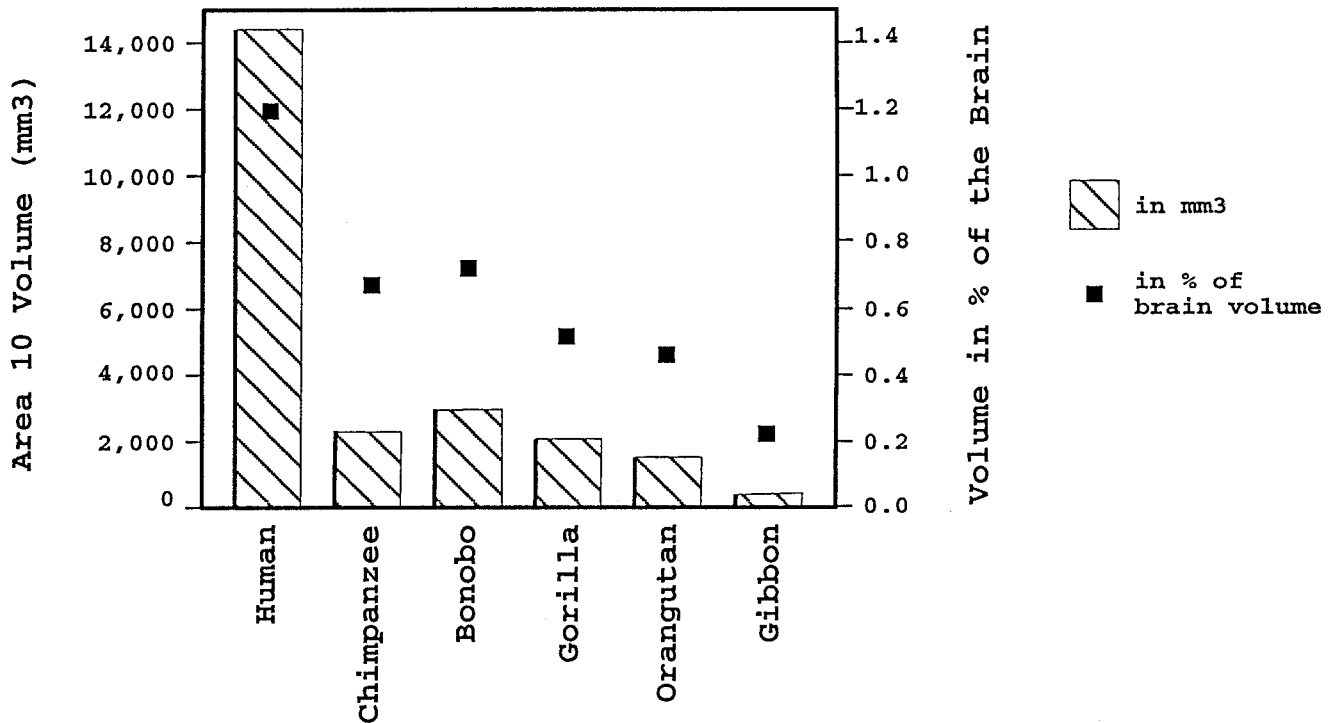


Fig. 7. Absolute and relative size of area 10 in right hemisphere. Columns represent absolute values in cubic millimeters, and squares represent relative values in percentage of total brain volume.

multiple staining techniques? Are there species-specific patterns in the organization or the size of area 10? What can be said about the evolution of this higher-order association area in the human and ape lines?

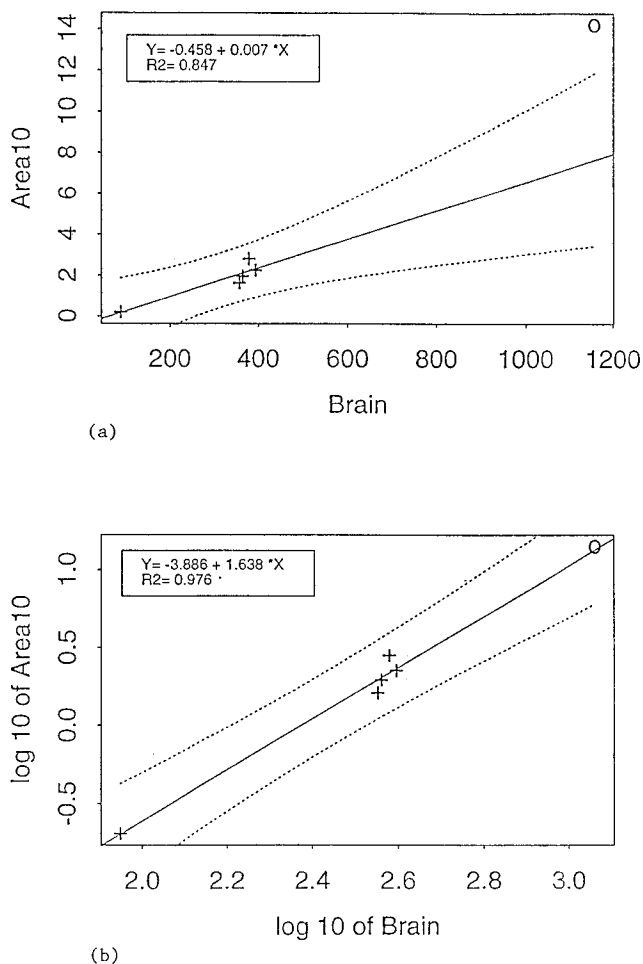
**Comparison with previous studies**

Brodmann (1909) studied comparatively the cortex of several primate species; in his maps, he introduces numbers for specific cortical areas in humans and other primates. Although area 10 in his human map refers to the frontal pole, the area designated as 10 that appears in his cercopithecoid map does not refer to the frontal pole of that species. "Area frontopolaris" of *Cercopithecus* is called "field 12," whereas area 10 refers to an "area orbitalis externa." It is of interest that Brodmann (1909) stated that the frontal pole in *Cercopithecus* corresponds more closely to area 11 in the human brain, and that a homology between the human and "monkey" frontal cortical types is very unclear. In contrast to Brodmann (1909) and in agreement with later studies (Walker, 1940; Petrides and Pandya, 1994), we were able to demonstrate the presence of a homologous area 10 in the frontal pole of humans and other primates.

Economo and Koskinas (1925) identified area FE as a distinct cortical type constituting the human frontal pole that corresponds to Brodmann's area 10. Economo and Koskinas (1925) recognized some variation in the structure of FE, and stated that FE is not the same everywhere. The findings of the

present study are in agreement with the general description of FE, though we have not identified any subdivisions of area 10 in the human brain.

The human, chimpanzee and macaque cortex were studied by Bonin and Bailey (1947; see also Bailey et al., 1950; Bailey and Bonin, 1951). This group did not assign letters or numbers to individual cortical areas, but instead subdivided the entire isocortex into a few major categories with no further subdivisions. Regarding the frontal cortices in humans, Bailey and Bonin (1951, p. 197) criticized any attempt (especially that of Economo and Koskinas, 1925) to identify multiple subdivisions. They stated, "Quite apart from the extreme variability of the pattern and size of the frontal gyri, it is evident that the distinction between FD and FE is very precarious and based on no feature which would seem from any viewpoint to be important." Although we appreciate the difficulties in identifying individual cortical areas, we were able to demonstrate the distinct presence of area 10, which forms the frontal pole in the human brain. Regarding the macaque, Bonin and Bailey (1947, p. 30) include the cortex constituting the frontal pole under FD, which "covers practically the entire frontal lobe anterior to the arcuate sulcus," and they discussed some of its variants (one is in the banks of the sulcus principalis, and another is in the anterior bank of the inferior limb of the arcuate sulcus). Bonin and Bailey (1947, p. 31) stated, "The cells become generally somewhat smaller as the tip is approached, as Economo has described for the human brain. One might on this basis label a



**Fig. 8.** Allometric plots in (a) linear scale and (b) log-log scale including best fit regression lines (least squares) through all nonhuman hominoid values. Crosses represent great and lesser apes; circles represent humans.

variant FDE." Of particular interest is their study of the chimpanzee frontal cortex. Bailey et al. (1950, p. 40) recognized as distinct (from FD) a cortical type that "has smaller and more closely packed cells than has FD," and that "the fourth layer is fairly thick; it contains a dense population of pale granules." Like Bailey et al. (1950), we identify a distinct area forming the frontal pole of chimpanzee area 10.

Sanides (1970) recognized a separate cortical type constituting the human frontal pole (the frontopolar zone or FpZ), which he described as a very thin, well-granularized cortex. Nevertheless, unlike our own observations, he stated that there are two components, a pars convexa and a pars orbitalis.

The findings of the present study are in agreement with the general description of area 10 in the macaque as provided by Walker (1940) and Preuss and Goldman-Rakic (1991). Walker (1940) placed area 10 on the frontal pole and the lateral part of the gyrus rectus. Preuss and Goldman-Rakic (1991) described the frontal pole in terms of the development of layer IV in Nissl staining and degrees of fiber myelination.

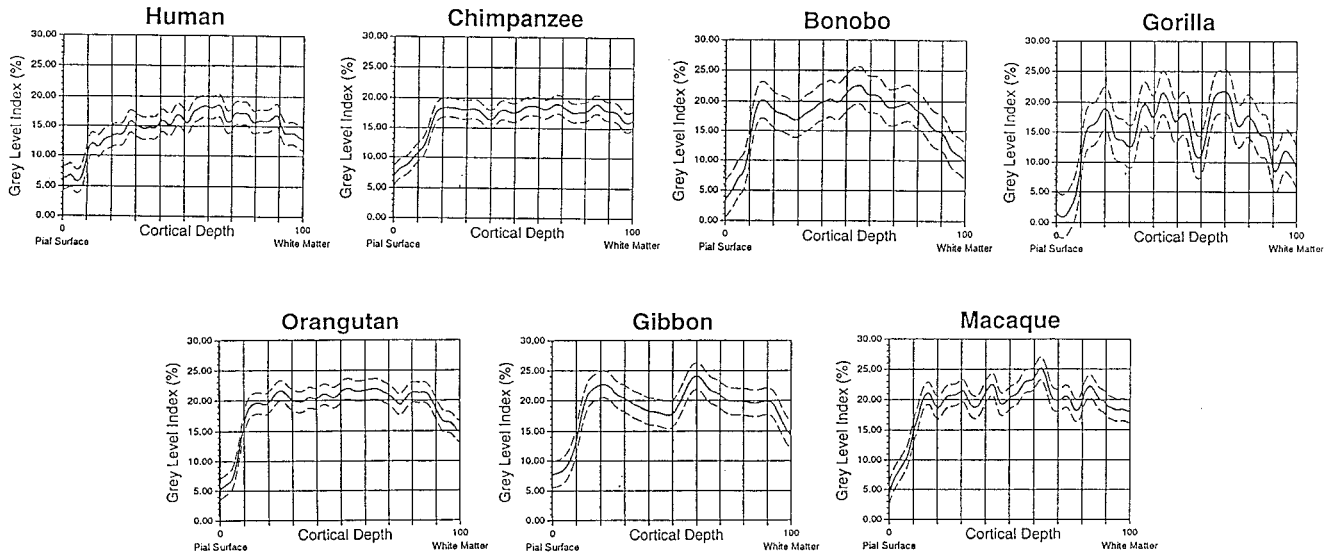
Our findings support in particular the idea discussed by Barbas and Pandya (1989), Morecraft et al. (1992), and Carmichael and Price (1994) in favor of the presence of two components in the frontal pole of the macaque. Barbas and Pandya (1989) described a mediodorsal and a ventrolateral component of area 10. Morecraft et al. (1992) identified in the macaque the orbital sector of the frontal pole (area 10) as part of the orbitofrontal granular cortex or, OFg. This type of cortex is characterized by increased granularization (in relation to more orbitally located cortices), which leads to the appearance of a six-layered granular cortex. Carmichael and Price (1994) also distinguished two components (orbital and medial) within the macaque frontal pole, on the basis of numerous immunocytochemical methods.

Petrides and Pandya (1994) identified, as we do in the present study, a homologous area 10 in the human and macaque frontal pole. They describe the frontal pole of the human brain as being cell-sparse and pale in its overall appearance, in comparison to the surrounding areas. Hof et al. (1995) mapped the human orbitofrontal cortex, using cytoarchitecture and immunohistochemistry. In the most anterior part of the orbital surface, they recognized a frontopolar area (FP). They suggested that FP corresponds to the cytoarchitecturally defined area 10 and part of Brodmann's area 11, as well as part of area FE of Economo and Koskinas (1925). In addition, their study revealed that this area of the orbital cortex is characterized by a relatively increased density of neurofilament protein-immunoreactive pyramidal neurons in layers III, V, and VI. We have not used immunohistochemistry in our study and, although we agree with regards to the identification and presence of area 10 on the orbital surface, we have not tested the idea of whether or not area 10 occupies part of Brodmann's area 11.

In summary, the cortex forming the frontal pole was identified in humans as area 10 (Brodmann, 1909; Petrides and Pandya, 1994), area FE (Economo and Koskinas, 1925), area FpZ (Sanides, 1970), and area FP (Hof et al., 1995); in the chimpanzee as area FE or FDE (Bailey et al., 1950); and in the macaque as area 10 (Walker, 1940; Preuss and Goldman-Rakic, 1991; Barbas and Pandya, 1989; Carmichael and Price, 1994) and also as part of area OFg in the orbital component of the frontal pole (Morecraft et al., 1992). Many studies on the macaque suggest that there is more than one component (orbital and dorsomesial) forming the frontal pole in the macaque, an idea supported by the present study.

#### Definition of hominoid area 10

Our results are in general agreement with most previous studies of the frontal pole of individual species. Here, in addition to the human, chimpanzee, and macaque, we identified area 10 in the frontal pole of the bonobo, orangutan, and gibbon (Fig.



**Fig. 9.** Grey-level index (GLI) profiles (solid lines represent mean values; dotted lines represent standard deviation) of human, chimpanzee, bonobo, and gorilla (above) and orangutan, gibbon, and macaque (below). Peaks in profiles represent areas covered more by cell bodies leaving less space available for connections.

**TABLE 3.** Grey-level index in area 10<sup>1</sup>

	Cortical mean <sup>2</sup>	Standard deviation	Layers	Layer mean <sup>3</sup>	Average standard deviation
Human	15.17	1.8926	II, III	14.40	1.9375
			IV	18.04	0.6749
			V, VI	16.04	1.6770
Chimpanzee	17.52	1.5751	II, III	16.69	2.6288
			IV	18.45	0.3298
			V, VI	17.95	1.0200
Bonobo	18.17	3.0265	II, III	18.95	2.4088
			IV	21.60	0.9547
			V, VI	16.21	3.4732
Gorilla	15.87	3.5655	II, III	16.43	3.2118
			IV	17.87	1.0712
			V, VI	15.05	4.2290
Orangutan	20.10	1.7282	II, III	19.81	1.9910
			IV	21.49	0.2924
			V, VI	19.65	2.2236
Gibbon	19.80	2.3440	II, III	19.43	2.4329
			IV	21.64	2.2680
			V, VI	19.56	1.9485
Macaque	20.34	1.8557	II, III	20.16	1.7844
			IV	24.03	0.9154
			V, VI	19.91	2.1464

<sup>1</sup> Values reflect percent of area occupied by cell bodies.

<sup>2</sup> Mean GLI values of cortical layers II–VI.

<sup>3</sup> Mean GLI values for the supragranular (II, III), granular (IV), and infragranular (V, VI) layers. Measurements were obtained from one hemisphere per species at multiple locations.

**TABLE 4.** Relative width of cortical layers in area 10<sup>1</sup>

	Mean	Standard deviation
Human		
Layer I	11.0	2.83
Layers II, III	43.0	2.83
Layer IV	6.0	1.41
Layers V, VI	40.0	1.41
Chimpanzee		
Layer I	11.5	3.54
Layers II, III	44.5	0.71
Layer IV	8.0	0.0
Layers V, VI	36.0	4.24
Bonobo		
Layer I	10.5	2.12
Layers II, III	46.5	3.54
Layer IV	8.0	1.41
Layers V, VI	35.0	7.1
Gorilla		
Layer I	10.0	1.41
Layers II, III	34.0	2.83
Layer IV	6.5	0.71
Layers V, VI	49.5	4.95
Orangutan		
Layer I	8.5	0.71
Layers II, III	37.0	4.24
Layer IV	7.5	0.71
Layer V, VI	47.0	4.24
Gibbon		
Layer I	9.0	0.0
Layers II, III	42.0	0.0
Layer IV	11.0	0.00
Layers V, VI	38.0	0.0
Macaque		
Layer I	11.5	2.12
Layers II, III	43.0	4.24
Layer IV	6.0	0.0
Layers V, VI	39.5	2.12

<sup>1</sup> Values are in percent of total cortical width. Measurements were obtained from one hemisphere per species at multiple locations.

11). In all of the above species, area 10 is characterized by the following: layer I is medium in width; layer II is thin and distinguishable, but not prominent; layer III is very wide and includes cells that are stained darkly and that are slightly larger superficial to layer IV, where their size is almost that of the pyramids in layer V; layer IV is clearly present, includes small cells, and has distinguishable borders with layers III and V; layer V has a slightly more prominent Va, which translates into larger, darkly stained pyramidal cells in high den-

sity; and layer VI has a medium size and a sharp border with the white matter.

Our small sample size allows only preliminary conclusions with regard to the quantitative mea-

TABLE 5. Neuronal density (per  $\text{mm}^3$ ) and total numbers of neurons in area 10<sup>1</sup>

Species	Density of neurons	SE	Total numbers
Human	34,014	2,700	254,400,000
Chimpanzee	60,468	5,650	64,500,000
Bonobo	55,690	6,300	63,500,000
Gorilla	47,300	4,300	45,900,000
Orangutan	78,182	5,800	63,000,000
Gibbon	86,190	6,250	8,000,000

<sup>1</sup> Estimates refer to one hemisphere (right) per species.

tures. Area 10 in the human, chimpanzee, and bonobo shares a similar ratio in relative width of the cortical layers. It has larger supragranular layers, known to be involved in short and long association connections, and smaller infragranular layers involved in connections with subcortical structures and, to some extent, long association connections (Table 4). In the rest of the hominoids the infragranular layers occupy a larger percent of the cortical depth, and in the macaque the two values are nearly equal. Layer IV neurons connect cortical neurons within functional columns and/or connect adjoining columns. Across all primates studied, layer IV is the thinnest layer and varies from 6–11%, followed by acellular layer I (9–11.5% of total cortical thickness).

With respect to the space occupied by cell bodies vs. neuropil space (largely occupied by connections), there are several observations based on the GLI

profiles (Fig. 10). As demonstrated by the similar shape of the profiles, humans and apes share throughout the depth of their cortex a similar relationship of space occupied by cell bodies vs. connections. It is also clear from the peaks in the profiles that the granular layer (layer IV) is the one with the highest concentration of cell bodies and less neuropil space across species. Furthermore, larger primate brains are known to have decreased cell-packing density when compared to smaller-sized primate brains (Armstrong, 1990); area 10 proves to be no exception. As evidenced by the relative position of the profiles (ape profile at the top and human profile at the bottom), this area is more densely packed with cell bodies in apes than in humans. This may indicate that area 10 in humans has more space available for extrinsic and intrinsic connections. Of particular interest is the fact that the supragranular layers stand out more in the human brain by having an even lower distribution of values when compared to the rest of the hominoids. Humans seem to have more space available for connections in layers II and III, which may indicate increased communication between area 10 and other higher-order association areas in our species.

Both the qualitative and quantitative observations of this study suggest that not all of the species studied share the same homogeneous patterns in the cortex of the frontal pole. Specifically, the gorilla frontal pole includes many of the cytoarchitectonic features described above, but also features that are

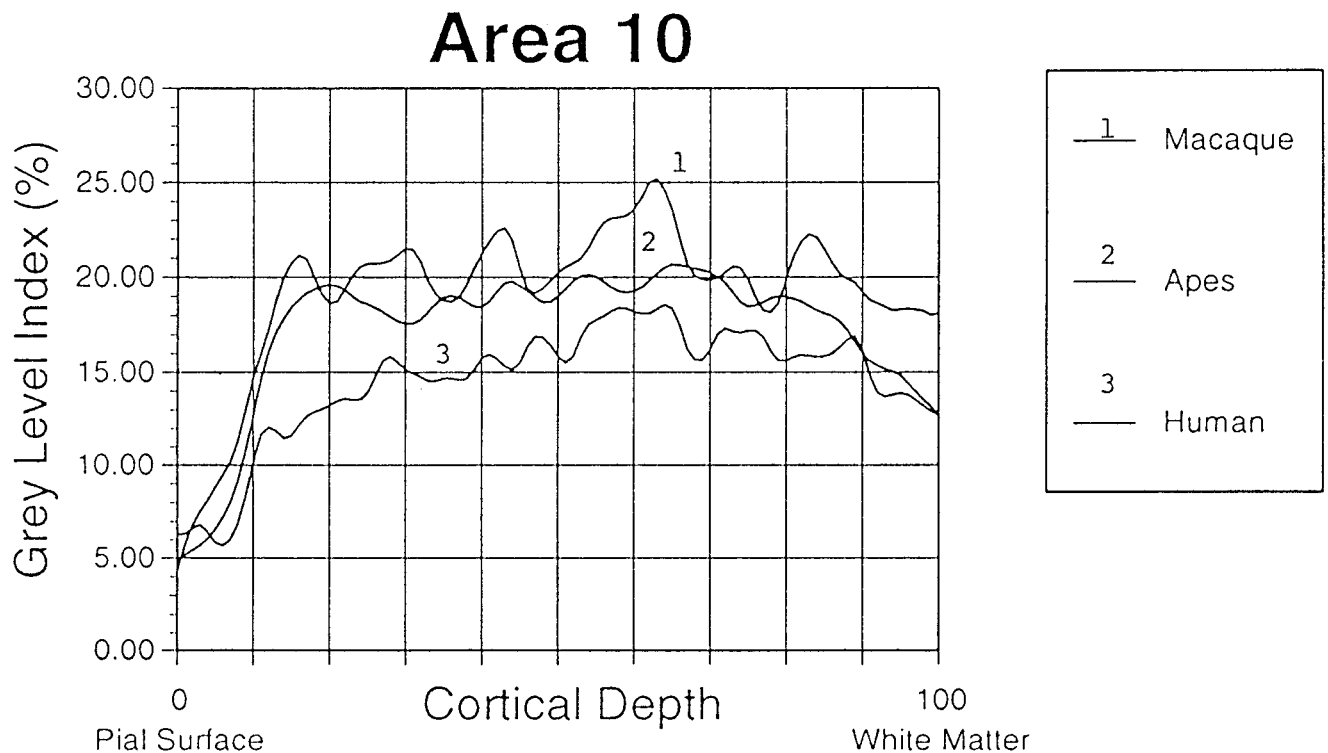


Fig. 10. Comparative plots of GLI profiles in area 10 of the human, ape, and macaque. The human profile has lower values in the part of the cortex occupied by supragranular layers.

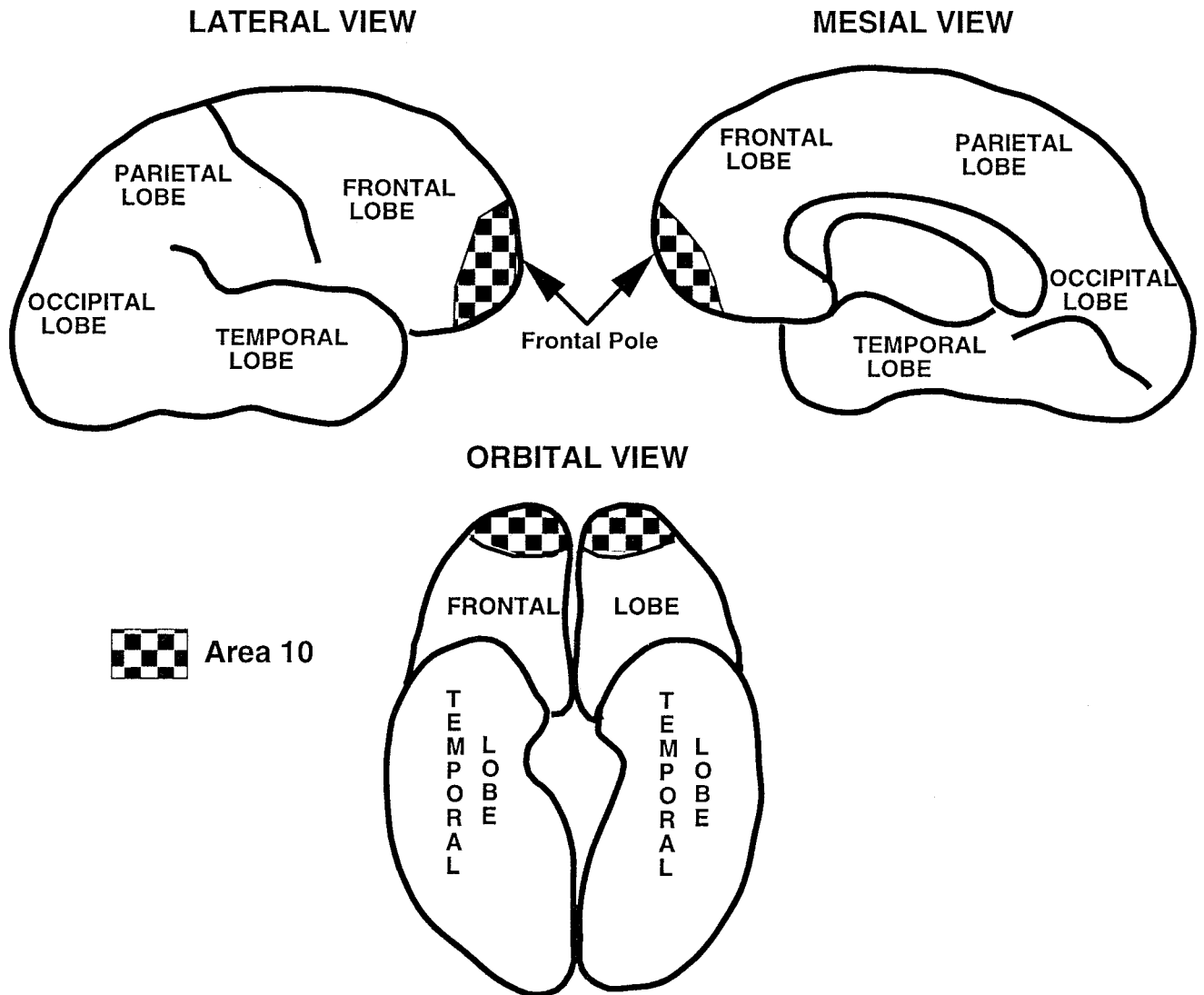


Fig. 11. Graphic representation of approximate location and extent of area 10 in the frontal pole of a hominoid brain.

absent in other hominoids that make homology with area 10 questionable. The distinct appearance of the cortex of the gorilla frontal pole may be related to a species-specific modification of area 10 or to the emergence of a new cortical area. It is of interest that many of the features characterizing the frontal pole in this great ape are present in the dorsal component of the gibbon frontal pole. The frontal pole of the gibbon, unlike that of other hominoids, is composed of two cortical areas. Area 10 forms the orbital component of the frontal pole and has an appearance very similar to the human, chimpanzee, bonobo, and orangutan frontal pole. The dorsal part of the frontal pole belongs to a separate cortical area (area 9?) that remains to be investigated. More specimens and additional immunostaining for cellular phenotypes are needed in order to clarify the issue. Finally, as was discussed in the literature review, many recent studies of the prefrontal cortex of the macaque support the presence of two distinct components, an

orbital and a dorsal (Barbas and Pandya, 1989; Morecraft et al., 1992; Carmichael and Price, 1994). These views are fully supported by qualitative observations made in this study which suggest the presence of a restricted, orbital component in the macaque frontal pole, one that shares most structural features with area 10 in the hominoids.

#### Evolutionary scenario

Consideration of the comparative information suggests that area 10 may have undergone a shift in its extent and topographic location during hominoid evolution. In primates ancestral to the extant hominoids, area 10 occupied a restricted location in the orbital part of the frontal pole. In the line leading to gibbons, the topographic location and probably the extent of area 10 did not change appreciably. In Asian and African large-bodied hominoids, area 10 came to occupy the entire frontal pole and is now present in orangutans, chimpanzees, bonobos, and



humans. The preliminary findings on the gorilla suggest that in the line leading to this great ape, area 10 was either selectively reorganized or shifted to a different location within the rostral prefrontal cortices.

During hominid evolution, area 10 underwent a couple of additional changes: one involves a considerable increase in overall size, and the other involves a specific increase in connectivity, especially with other higher-order association areas. It was shown that the frontal lobe as a whole is not differentially enlarged in humans (Semendeferi and Damasio, 2000), but individual cortical areas, like area 13 (Semendeferi et al., 1998) and area 10, seem to vary in size.

Area 10 in the human brain appears to be specialized in size and organization, which suggests that functions associated with this part of the cortex have become particularly important during hominid evolution. Planning of future actions and the undertaking of initiatives are hallmarks of human behavior, and although present to some extent in other hominoids and possibly other primates, they became fully expressed in the Plio-Pleistocene hominids.

### CONCLUSIONS

Earlier studies of prefrontal cortices suggested that area 10 is present in the frontal pole of macaque and human brains, but comparative studies of this part of the cortex in apes were few. It is shown here that area 10 is also present in chimpanzee, bonobo, orangutan, and gibbon brains, and is characterized by similar cytoarchitectonic features. Nevertheless, aspects of its organization vary slightly across species. In the large-bodied hominoids, area 10 occupies the entire frontal pole, while in the gibbon it is restricted to the orbital sector. The gorilla seems to be highly specialized, and the questionable presence of this area needs to be further investigated. Humans have a larger area 10 than apes and also specialized cortical layers involved in connections with other higher-order association areas. The quantification of larger samples of great ape brain tissue stained with multiple techniques is imperative if we are to understand the evolution of the neural substrates of cognition in humans and apes.

### ACKNOWLEDGMENTS

We thank Busch Gardens Zoo and Yerkes Regional Primate Research Center for the ape specimens, K. Amunts for helpful comments, U. Blohm for technical support, P. Reimann for photography, T. Wolfson for statistical consultations, N. Xenitopoulos for technical and graphic support, and D. Tuzin for editorial comments.

### LITERATURE CITED

Armstrong E. 1990. Evolution of the brain. In: Paxinos G, editor. The human nervous system. New York: Academic Press. p 1–16.

- Bailey P, Bonin G. 1951. The isocortex of man. Urbana: University of Illinois Press.
- Bailey P, Bonin G, McCulloch WS. 1950. The isocortex of the chimpanzee. Urbana: University of Illinois Press.
- Barbas H, Pandya DN. 1989. Architecture and intrinsic connections of the prefrontal cortex in the rhesus monkey. *J Comp Neurol* 286:353–375.
- Bonin G, Bailey P. 1947. The neocortex of *Macaca mulatta*. Urbana: University of Illinois Press.
- Brodman K. 1909. Vergleichende Lokalisationslehre der Grosshirnrinde. Leipzig: Barth.
- Carmichael ST, Price JL. 1994. Architectonic subdivision of the orbital and medial prefrontal cortex in the macaque monkey. *J Comp Neurol* 346:366–402.
- Daffner KR, Mesulam MM, Scinto LF, Acar D, Calvo V, Faust R, Chabrier A, Kennedy B, Holcomb P. 2000. The central role of the prefrontal cortex in directing attention to novel events. *Brain* 123:927–939.
- Damasio AR. 1985. The frontal lobes. In: Heilman K, Valenstein E, editors. Clinical neuropsychology. Oxford: Oxford University Press. p 339–375.
- Economo C, Koskinas GN. 1925. Die Cytoarchitectonik der Hirnrinde des Erwachsenen Menschen. Berlin: Verlag von Julius Springer.
- Gallyas F. 1971. A principle for silver staining of tissue elements by physical development. *Acta Morphol Acad Sci Hung* 19:57–71.
- Gundersen HJG, Bendtsen TF, Korbo L, Marcussen N, Moller A, Nielsen K, Nyengaard JR, Pakkenberg B, Sorensen FB, Vesterby A, West MJ. 1988a. Some new, simple and efficient stereological methods and their use in pathological research and diagnosis. *Acta Pathol Microbiol Immunol Scand* 96:379–394.
- Gundersen HJG, Bagger P, Bendtsen TF, Evans SM, Korbo L, Marcussen N, Moller A, Nielsen K, Nyengaard JR, Pakkenberg B, Sorensen FB, Vesterby A, West MJ. 1988b. The new stereological tools: dissector, fractionator, nucleator and point sampled intercepts and their use in pathological research and diagnosis. *Acta Pathol Microbiol Immunol Scand* 96:857–881.
- Harlow HF, Akert K, Schiltz KA. 1964. The effects of bilateral prefrontal lesions on learned behavior of neonatal, infant and preadolescent monkeys. In: Warren JM, Akert K, editors. The frontal granular cortex and behavior. New York: McGraw-Hill Book Co. p 126–148.
- Hof PR, Mufson EJ, Morrison JH. 1995. Human orbitofrontal cortex: cytoarchitecture and quantitative immunohistochemical parcellation. *J Comp Neurol* 359:48–68.
- Hyman BT, Gomez-Isla T, Irizarry MC. 1998. Stereology: a practical primer for neuropathology. *J Neuropathol Exp Neurol* 57:305–310.
- Lepage M, Ghaffar O, Nyberg L, Tulving E. 2000. Prefrontal cortex and episodic memory retrieval mode. *Proc Natl Acad Sci USA* 97:506–511.
- Merker B. 1983. Silver staining of cell bodies by means of physical development. *J Neurosci Methods* 9:235–241.
- Morecraft RJ, Geula C, Mesulam MM. 1992. Cytoarchitecture and neural afferents of orbitofrontal cortex in the brain of the monkey. *J Comp Neurol* 323:341–358.
- Okuda J, Fujii T, Yamadori A, Kawashima R, Tsukiura T, Fukatsu R, Suzuki K, Ito M, Fukuda H. 1998. Participation of the prefrontal cortices in prospective memory: evidence from a PET study in humans. *Neurosci Lett* 253:127–130.
- Petrides M, Pandya DN. 1994. Comparative architectonic analysis of the human and the macaque frontal cortex. In: Boller F, Grafman J, editors. Handbook of neuropsychology, volume 9. Amsterdam: Elsevier Science, p 17–58.
- Preuss TM, Goldman-Rakic PS. 1991. Myelo- and cytoarchitecture of the granular frontal cortex and surrounding regions in the strepsirhine primate Galago and the anthropoid primate Macaca. *J Comp Neurol* 310:429–474.
- Rajkowska G, Goldman-Rakic PS. 1995a. Cytoarchitectonic definition of prefrontal areas in the normal human cortex: I.

- Remapping of areas 9 and 46 using quantitative criteria. *Cereb Cortex* 5:307–322.
- Rajkowska G, Goldman-Rakic PS. 1995b. Cytoarchitectonic definition of prefrontal areas in the normal human cortex: II. Variability in locations of areas 9 and 46 and relationship to the Talairach coordinate system. *Cereb Cortex* 5:323–337.
- Rosvold H, Enger A, Szwarcbart IG. 1964. Neural structures involved in delayed response performance. In: Warren JM, Akert K, editors. *The frontal granular cortex and behavior*. New York: McGraw-Hill Book Co. p 1–15.
- Sanides F. 1964. Structure and function of the human frontal lobe. *Neuropsychology* 2:209–219.
- Sanides F. 1970. Functional architecture of motor and sensory cortices in primates in the light of a new concept of neocortex evolution. In: Nobak CR, Montagna W, editors. *The primate brain*. New York: Appleton-Century-Crofts. p 137–208.
- Schlaug G, Armstrong E, Schleicher A, Zilles K. 1993. Layer V Pyramidal cells in the adult human cingulate cortex: a Quantitative Goldi-study. *Anat Embryol (Berl)* 187:515–522.
- Schleicher A, Zilles K. 1989. A quantitative approach to cytoarchitectonics: analysis of structural inhomogeneities in nervous tissue using an image analyzer. *J Microsc* 157:367–381.
- Semendeferi K, Damasio H. 2000. The brain and its main anatomical subdivisions in living hominoids using magnetic resonance imaging. *J Hum Evol* 38:317–332.
- Semendeferi K, Armstrong E, Schleicher A, Zilles K, Van Hoesen GW. 1998. Limbic frontal cortex in hominoids: a comparative study of area 13. *Am J Phys Anthropol* 106:129–155.
- Walker AE. 1940. A cytoarchitectural study of the prefrontal area of the macaque monkey. *J Comp Neurol* 73:59–86.
- West MJ, Gundersen HJG. 1990. Unbiased stereological estimation of the number of neurons in the human hippocampus. *J Comp Neurol* 296:1–22.
- West MJ, Slomianka L, Gundersen HJG. 1991. Unbiased stereological estimation of the total number of neurons in the subdivisions of the rat hippocampus using the optical fractionator. *Anat Rec* 231:482–497.