

# Study of 250 Children With Idiopathic Mental Retardation Reveals Nine Cryptic and Diverse Subtelomeric Chromosome Anomalies

Elizabeth Baker,<sup>1,2</sup> Lyn Hinton,<sup>1</sup> David F. Callen,<sup>1,3</sup> Meryl Atree,<sup>4</sup> Angus Dobbie,<sup>4</sup> Helen J. Eyre,<sup>1</sup> Grant R. Sutherland,<sup>1,3</sup> Elizabeth Thompson,<sup>4</sup> Peter Thompson,<sup>5</sup> Erica Woollatt,<sup>1</sup> and Eric Haan<sup>4\*</sup>

<sup>1</sup>Centre for Medical Genetics, Department of Cytogenetics and Molecular Genetics, Women's and Children's Hospital, Adelaide, Australia

<sup>2</sup>Department of Paediatrics, University of Adelaide, Adelaide, Australia

<sup>3</sup>Department of Molecular Biosciences, University of Adelaide, Adelaide, Australia

<sup>4</sup>South Australian Clinical Genetics Service, Women's and Children's Hospital, Adelaide, Australia

<sup>5</sup>University Hospital of Wales, Cardiff, Wales

Cryptic subtelomeric chromosome anomalies have been recognized as a significant cause of dysmorphism and mental retardation. To determine whether the clinical cytogenetics laboratory should screen routinely for these aberrations, we have tested 250 patients with idiopathic mental retardation/developmental delay, either isolated (53) or associated with dysmorphic features and/or malformations in the absence of a recognizable syndrome (197). All had normal karyotypes at the 550–850 band level. Subtelomeric anomalies were found in 1/53 of the first group (1.9%) and 8/197 of the second group (4.1%). In one patient, two separate anomalies were present: a deletion (not inherited) and a duplication (inherited). It is possible that one of these 10 observed aberrations might represent a rare and previously unreported polymorphism and one a rare cross-hybridization. Our study supports the proposition that cryptic subtelomeric rearrangements are a significant cause of idiopathic mental retardation/developmental delay, but both the diversity of the phenotypes of the positive cases and the wide diversity of their associated chromosome abnormalities emphasize the central problem for the clinical cytogenetics

laboratory—that of choosing the most productive patient base for this useful diagnostic test. © 2001 Wiley-Liss, Inc.

**KEY WORDS:** idiopathic mental retardation; subtelomeric rearrangements; cryptic chromosome abnormalities

## INTRODUCTION

Cryptic rearrangements involving the subtelomeric regions of chromosomes have emerged as an important cause of human dysmorphism and mental retardation [Flint et al., 1995; Reddy and Fugate, 1999; Knight and Flint, 2000]. The technical problems associated with designing a highly sensitive and unique set of probes capable of detecting such rearrangements have been largely overcome by the availability of sequence information from the Human Genome Project, in particular by the isolation and characterization of a set of FISH probes initially described by the National Institutes of Health and Institute of Molecular Medicine Collaboration [1996] and updated in 2000 [Knight et al., 2000]. It is probable that subtelomere screening will eventually be performed by molecular-based methods such as DNA arrays, multiplex amplifiable probe hybridization (MAPH) [Sismani et al., 2001], or real-time PCR [Jung et al., 2000]. The FISH-based approach provides a useful intermediate step, relatively straightforward and easy to incorporate into a working clinical cytogenetics laboratory. We have compiled a robust set of PAC, BAC, and P1 probes from a number of sources and applied them to the detection of all 41 subtelomeres in 250 patients, 53 with isolated idiopathic mental retardation/developmental delay and 197 with mental retardation/developmental delay associated with dysmorphic features and/or birth defects. Our object was to establish whether adding our own

Grant sponsor: The WCH Foundation; Grant sponsor: The APEX Foundation; Grant sponsor: The Wellcome Trust.

\*Correspondence to: Dr. Eric Haan, South Australian Clinical Genetics Service, Women's and Children's Hospital, 72 King William Road, North Adelaide SA 5006, Australia.

E-mail: haane@mail.wch.sa.gov.au

Received 9 August 2001; Accepted 4 October 2001

positive cases to those of recent studies [de Vries et al., 2001; Rossi et al., 2001] would help determine the most appropriate patient base for this useful diagnostic test.

## MATERIALS AND METHODS

There were two parts to the study. The first involved consecutive patients referred to our laboratory for routine cytogenetics between January 1998 and May 2001. The criteria for inclusion were the referring doctor mentioned mental retardation or developmental delay, together with dysmorphic features and/or malformations on the test request form, or the referring doctor listed two or more malformations in a neonate (whose developmental potential was unknowable at that point in time), and the banded karyotype was normal at the 550–850 band level. The study commenced in January 2000, so new blood samples were obtained from individuals originally studied in 1998 and 1999. The second part involved consecutive patients referred to our laboratory for routine cytogenetics between January and May 2001. The criteria for inclusion were the referring doctor mentioned mental retardation or developmental delay only on the test request form and the banded karyotype was normal at the 550–850 band level. Table I provides a summary of the clinical features of the nine patients with cryptic subtelomeric abnormalities. Patient 1 is from the group of 53 patients with isolated mental retardation/developmental delay. Patients 2 to 9 are from the group of 197 patients with mental retardation/developmental delay associated with dysmorphic features and/or malformations in the absence of a recognizable syndrome.

### Patient 1

A 5-year-old female with moderate intellectual disability overall (Denver II) and marked speech delay, short stature (height 97.5 cm, < third centile), hypermetropia and associated strabismus, upslanting palpebral fissures (a familial characteristic), dysplastic fifth toe nails, and a single small café-au-lait patch. Head circumference was near the 50th centile. There was a past history of a prolonged generalized seizure at 4.5 years of age; antiepileptic medication was not commenced and seizures did not recur. The pregnancy and perinatal period were normal. Birth weight was 2,990 g at 39 weeks. She had four siblings. A 15-year-old brother was described as a slow learner and was receiving remedial English education and a 12-year-old brother had borderline intellectual disability. An 8.5-year-old brother and a 7.5-year-old sister had no problems with learning. Both parents described themselves as having struggled at school and left school after 2 and 3 years of high school, respectively.

### Patient 2

A 6-year-old female with moderate global intellectual disability and mild dysmorphic features (dense hair, prominent forehead, large mouth, thin upper lip, and thick lower lip). Height was on the 10th centile and

head circumference near the 50th centile. The pregnancy and perinatal period were normal. Birth weight was 3,700 g. The proband's parents and siblings had normal intelligence and the parents had had a previous pregnancy terminated at 20-week gestation because of hydrops fetalis. A paternal aunt was described as having cerebral palsy and intellectual disability. The wife of a paternal great-uncle had eight miscarriages.

### Patient 3

A 12-year-old female with IQ (WISC-III) at the lower end of the low average range (80–89) overall, with verbal score at the lower end of the borderline range (70–79) and performance score in the average range (90–109). She was assessed to have a mild-moderate receptive language disorder, a moderate-severe expressive language disorder and delayed motor skills. She had mild dysmorphic craniofacial features (small epicanthic folds, upslanting palpebral fissures, depressed nasal bridge, short philtrum), long and slender fingers, and narrow feet with long toes. Height was on the 75th centile and head circumference near the 50th centile. Mild pulmonary valve stenosis and a large ventricular septal defect were diagnosed soon after birth; the septal defect was corrected surgically. Vesicoureteric reflux was documented at 15 months following a urinary tract infection. She had chronic serous otitis media treated with grommets. The pregnancy and perinatal period were normal. Birth weight was 3,520 g. There was no family history of intellectual disability.

### Patient 4

A 16-year-old male with severe intellectual disability, short stature (height 146 cm, < third centile), microcephaly (head circumference at 11 years 48.3 cm, < second centile), mild dysmorphic craniofacial features (low posterior hairline, deep-set eyes, lack of eyelashes medially, and a narrow chin), broad and short terminal phalanges of the thumbs, bilateral clinodactyly of the little fingers, and shortening of the third, fourth, and fifth toes bilaterally. He had abnormal behaviors, including self-injury, repetitive play, and obsessions, and his features met the criteria for a diagnosis of autism. There was a past history of bilateral inguinal herniae. The pregnancy and perinatal period were normal. Birth weight was 2,500 g at 37-week gestation. His features were consistent with those described in the chromosome 1p36 deletion syndrome [Shapira et al., 1997]. There was no family history of intellectual disability.

### Patient 5

A 17-year-old male with moderate global intellectual disability, short stature (height 153.5 cm, < third centile), microcephaly (head circumference 51.8 cm, < second centile), mild glandular hypospadias, dysmorphic craniofacial features (low set simple ears, mild facial asymmetry, hypotelorism, short palpebral fissures, prominent broad nose, high arched palate),

TABLE I. Clinical Features of Nine Patients With Cryptic Subtelomeric Abnormalities\*

	Case 1	Case 2	Case 3	Case 4	Case 5	Case 6	Case 7	Case 8	Case 9
Subtelomeric rearrangement	22q-	5q-, 16q+	5q-, 16q+	1p-	9q+, 14q-	20p-	1p+, 1q-	12p-	1p-, 9p+
Rearrangement familial	No	Yes	No	NK	Yes	Yes	NK	Yes	1p-, no; 9p+, yes
Age (years)/sex	5/F	6/F	12/F	16/M	17/M	10/M	15/M	14/M	5/F
Intellectual disability	Moderate	Moderate	Receptive and expressive language disorder	Severe	Moderate	Moderate	Borderline	Moderate	Moderate
Head circumference (centile)	50th	50th	50th	<2nd	<2nd	2nd	2nd-50 <sup>th</sup>	75th	2nd-50th
Height (centile)	<3rd	10th	75th	<3rd	<3rd	25th	3 <sup>rd</sup>	25th	<3rd
Dysmorphic craniofacial features	No	Yes	Yes	Yes	Yes	Yes	Yes	Minimal	Yes
Other dysmorphic features	Dysplastic 5th toe nails	No	Finger shape	Finger and toe shape and length	Finger shape and skin creases, pes cavus	Pes planus	Short distal phalanges	Short neck, kyphoscoliosis	Lumbar lordosis, small feet, syndactyly 2nd and 3rd toes
Malformations	No	No	Pulmonary stenosis, ventricular septal defect, vesicoureteric reflux	Inguinal herniae	Hypospadias	No	Undescended testes	Right sided aortic arch	Ventricular septal defect
Other features	Prolonged seizure			Autism, self-injury	Aggression, self-injury	Epilepsy		Aggression	Seizures at 5 weeks
Birth weight	AGA	AGA	AGA	AGA	SGA	NK	AGA	LGA	SGA
Score using checklist of de Vries et al. [2001]	2	2	3	6	9	4	6	3	7

\*AGA, appropriate for gestational age; SGA, small for gestational age; NK, not known; LGA, large for gestational age.

slender fingers with narrow distal phalanges, absence of the distal interphalangeal creases of the middle and ring fingers and pes cavus. There was a past history of aggression and self-injury. The pregnancy was normal apart from intrauterine growth restriction (birth weight 1,880 g at 38-week gestation). Hypotonia and feeding difficulties were present in the neonatal period. There was an extensive family history of similar problems [Anyon, 1965].

#### Patient 6

A 10-year-old male with moderate global intellectual disability (WISC-III), microcephaly (head circumference 50.5 cm, second centile), dysmorphic craniofacial features (long face, deep-set eyes, upslanting palpebral fissures, short philtrum and small mouth), and pes planus. It was noted that his face resembled those of his mother and brother. Height was on the 25th centile. There was a past history of generalized epilepsy from 7 years of age. The secondary dentition was delayed. The pregnancy was complicated by gestational diabetes, but the perinatal period was normal. Both the proband's parents are reported to be intellectually disabled but were not seen.

#### Patient 7

A 15-year-old male with borderline intellectual disability (IQ 75), short stature (height 165 cm, third centile), attention-deficit hyperactivity disorder improved by stimulant medication, dysmorphic craniofacial features (long face, almond-shaped eyes, upslanting palpebral fissures, thick eyebrows, broad nasal base with fleshy nares, relatively smooth philtrum, and a thin upper lip), and shortening of the distal phalanges of the fingers. Head circumference was normal (54.5 cm, 2nd–50th centile). There was a past history of strabismus corrected surgically. The pregnancy was normal and followed ovulation induction with clomiphene. Spontaneous labor occurred at term and was associated with breech presentation and fetal distress. Delivery was by assisted breech with forceps to the aftercoming head. The umbilical cord was wound tightly around the neck. Apgar scores were 0 at 1 min, 2 at 5 min, 4 at 10 min, and 7 at 15 min. Birth weight was 3,500 g, birth length was 50 cm, and birth head circumference was 35 cm. He had three seizures during the first 6 hr, controlled with phenobarbitone and phenytoin, and required oxygen for 24 hr. There was evidence of hypoxic damage to the kidneys and heart in the first days of life. A cerebral CT scan at 5 days of age was normal. Nasogastric feeding was necessary for 2.5 weeks, after which he fed orally at the breast with complementary formula feeds. Bilateral undescended testes were treated by orchidopexies at 6 and 7 months of age. He has not developed features of cerebral palsy in spite of apparent intrapartum asphyxia. The proband's parents have normal intelligence. His 11-year-old sister had dyslexia, problems with motor skills and height on the third centile. His 7-year-old brother had attention-deficit hyperactivity disorder, difficulties with motor skills, and height on the 50th centile.

#### Patient 8

A 14-year-old male with moderate intellectual disability overall (WISC-III), verbal abilities in the moderately delayed range, and performance abilities in the mildly delayed range, minimal dysmorphic craniofacial features (prominent ears, deep-set eyes), short neck, thoracic kyphoscoliosis, and right-sided aortic arch. He had aggressive behavior. Height was on the 25th centile and head circumference on the 75th centile. There was a past history of multiple hospital admissions in infancy for respiratory infections and diarrhea, in part the result of lactose intolerance. The pregnancy and perinatal period were normal. Birth weight was 4,400 g at 38 weeks. Mother attended a special school because of learning difficulties of undefined degree. Father had normal intelligence. The proband's three sisters had problems with school and his brother had mild learning difficulties.

#### Patient 9

A 5-year-old female with moderate intellectual disability, short stature (height 95.7 cm, < third centile), dysmorphic craniofacial features (telecanthus, downslanting palpebral fissures, flat mid-face with small and flat nose), a prominent lumbar lordosis, small feet, and mild syndactyly of second and third toes. Head circumference was 48.0 cm (2nd–50th centile). A small ventricular septal defect closed spontaneously at 3 months of age. The anterior fontanelle was large during the first year of life. There was a cluster of generalized seizures over 2 days at 5 weeks of age. The pregnancy and perinatal period were normal. Birth weight was 2,690 g at 40 weeks (< 10th centile). There was no family history of intellectual disability.

#### Cytogenetic Analysis

Cytogenetic analysis was performed on GTL-banded peripheral blood lymphocytes. All karyotypes were normal at the 550–850 band level.

#### Subtelomere Probe Set

Fluorescence in situ hybridization studies were performed using a set of probes specific for the subtelomeres of all chromosomes, mapping within 500 kb of their respective telomeres. These comprise 38 PAC, P1, or BAC probes, 35 of which are identical to those published by Knight et al. [2000], and three alternative probes (1p: PAC203K6; 2q: PAC210E14; Xq/Yq: BAC879P22). These were acquired from Incyte Genomics, from Children's Hospital Oakland (Oakland, CA), and kindly donated by J. Flint (Institute of Molecular Medicine, John Radcliffe Hospital, Oxford, U.K.). The remaining three probes in the set include a 61 kb cosmid contig comprising the most distal unique DNA from 16qter [Whitmore et al., 1998]; the probe c34F5, which encompasses the *SHOX* gene on Xp/Yp [Rao et al., 1997] kindly donated by G. Rappold (Institute of Human Genetics, Heidelberg University, Germany); and the P1 probe 9H11 in the subtelomeric region of

21q, kindly donated by A. Fujiyama (National Institute of Genetics, Shizuoka, Japan; <http://hgp.gsc.riken.go.jp/>).

For the FISH analysis, four slides per person were each divided into six sections with a diamond pencil and 4  $\mu$ l metaphase suspension was placed onto each section. The subtelomeric probes were directly labeled with SpectrumOrange or SpectrumGreen (Vysis) according to the manufacturer's instructions, and those probes corresponding to one chromosome (e.g., SpectrumOrange-labeled 1p and SpectrumGreen-labeled 1q) were cohybridized to the metaphases, one chromosome per section, i.e., six chromosomes per slide, using a PCR machine with a flatblock (Hybaid).

### Other FISH Studies

For further FISH studies of patient 8, a contig of PAC and BAC probes from distal 12p was purchased from Children's Hospital Oakland; the probe positions were ascertained through the Albert Einstein College of Medicine (<http://sequence.aecom.yu.edu/chr12>). Labeling and hybridization were as above.

For the X-inactivation studies of patient 9, 50 mg/l BrdU was added to short-term peripheral blood leucocyte cultures 7 hr prior to harvest. Slides were stained for 30 min in 2 mg Hoechst/50 ml 2  $\times$  SSC, rinsed in distilled water, air-dried, and exposed to UV light for 30 min. FISH was performed with the subtelomeric probes for Xq (SpectrumGreen) and 9p (SpectrumOrange) using the methodology described above.

## RESULTS

Table I provides a summary of the cryptic subtelomeric rearrangements detected in this study and the clinical features of the patients. Figure 1 shows the pedigrees of the 9 patients and summarizes cytogenetic testing of their families.

Patient 1 is from the group of patients with isolated mental retardation/developmental delay. Patients 2 to 9 are from the group of patients with mental retardation/developmental delay associated with dysmorphic features and/or malformations in the absence of a recognizable syndrome.

### Patient 1

Subtelomere testing detected strong fluorescent signal on one chromosome 22 using PAC99K24 but either no signal or very faint qter signal on its homolog (Fig. 2). FISH analysis of the mother, the father, and the sibling with learning difficulties showed normal signal on both chromosomes 22 (100 metaphases scored for each parent).

### Patient 2

Subtelomere testing detected an unbalanced rearrangement in the proband resulting in monosomy of 5qter and trisomy of 16qter. The karyotype was 46,XX, ish der(5)t(5;16)(q35.3;q24.3)(PAC240G13 -;c372B12/

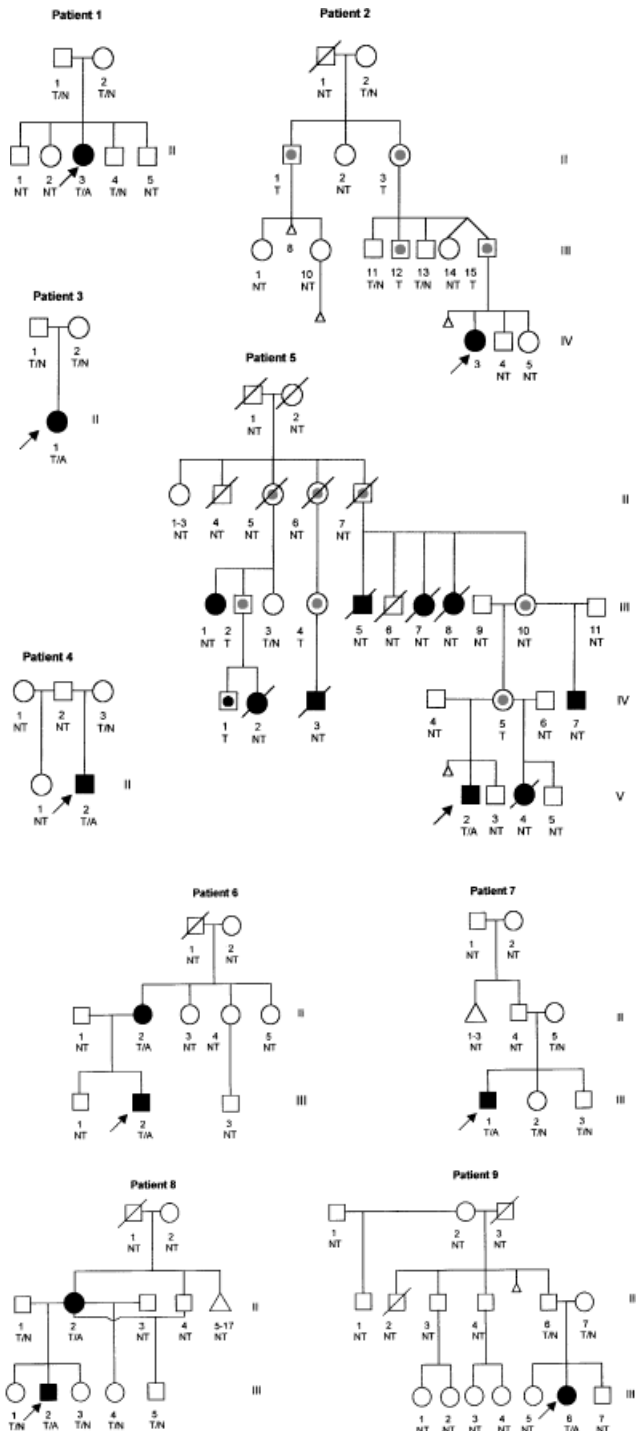


Fig. 1. Pedigrees of families with subtelomeric abnormalities. Filled symbols represent clinically affected individuals and open symbols represent clinically unaffected individuals. T or NT indicates patients whose subtelomeres were tested or not tested, respectively. T/A represents an individual who was tested and shown to carry an unbalanced cytogenetic anomaly. T/N represents an individual who was tested and shown to have normal subtelomeres. Symbols containing a dot indicate obligate or proven carriers of the cytogenetic anomaly.

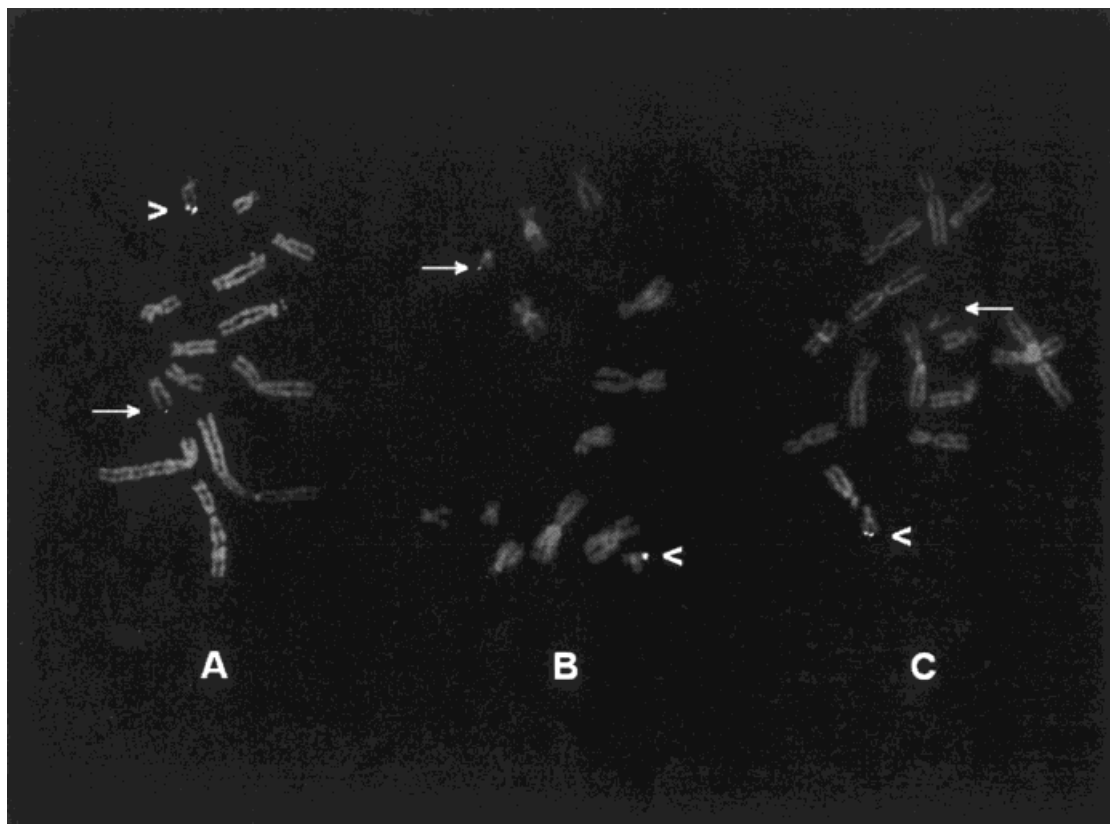


Fig. 2. Partial metaphases showing subtelomeric FISH with PAC99K24 to chromosomes from patient 1. **A** and **B**: Normal signal on one 22q (arrowhead) and reduced signal on the homolog (arrow). **C**: Normal signal on one 22q (arrowhead) and no signal on the homolog (arrow).

c301F3+). The proband's father and three paternal relatives were found to be carriers of the balanced translocation  $t(5;16)(q35.3;q24.3)$ . Studies are underway to determine the breakpoint within chromosome 16q24.3.

### Patient 3

Subtelomere testing detected an unbalanced rearrangement in the proband resulting in monosomy of 5qter and trisomy of 16qter. The karyotype in patient 3 was identical to that in patient 2. FISH analysis of both parents was normal and as no connection could be established between the families of patients 2 and 3, the proband's karyotype is presumed to have arisen de novo. When the chromosome 16 breakpoint has been established for patient 2, we will determine whether it is identical to that in patient 3.

### Patient 4

Subtelomere testing detected a deletion of the terminal region of 1p using PAC203K6. FISH analysis of the mother was normal. The father was unavailable for study.

### Patient 5

Subtelomere testing detected an unbalanced rearrangement in the proband resulting in monosomy of

14qter and trisomy of 9qter. The karyotype was  $46,XY.ish\ der(14)t(9;14)(q34.3;q32.33)(PAC112N13+; PACdJ820M16-)$ . The balanced form of the translocation was found in the mother and three maternal relatives.

### Patient 6

Subtelomere testing detected a deletion of 20pter using PACdJ1061L1. The proband's similarly affected mother was found to have the same deletion. No other family members were available for study.

### Patient 7

Subtelomere testing showed an abnormal result for the chromosome 1 probes. Signal for the 1p PAC203K6 and the 1q PAC160H23 were present as usual at the pter and qter regions of one homolog, but 1p signal was present at both the pter and qter regions of the second chromosome 1 and signal from the 1q probe was missing. This was interpreted as a derivative chromosome 1 resulting from a large parental pericentric inversion. FISH results for the mother and two siblings were normal. The father was not available for study, nor were three paternal relatives with learning difficulties, behavior disorder, and cleft palate, respectively.

### Patient 8

Subtelomere testing detected a deletion of 12pter using PAC496A11. FISH studies of the mother, who had learning difficulties at school, showed that she carried the same deletion (100 metaphases scored). The father, two siblings, and two maternal half-siblings all gave normal FISH results. No other family members were available for testing. FISH studies with the contig of probes in distal 12p have refined the breakpoint in the patient and his mother to the region between RPCI-3-340I3 (~1.5 Mb from the telomere) and RPCI-11-288K12 (~1.7 Mb from the telomere). This work is continuing.

### Patient 9

Subtelomere testing gave an unusual result for two probes. A deletion of the 1pter PAC203K6 was detected, and an extra copy of the 9pter probe PAC43N6 was present in band q21.3 of one of the proband's X chromosomes (Fig. 3). FISH results for the father gave normal results for the 1pter probe, but the result for the 9pter probe appeared identical to that in his daughter, that is, an extra copy of 9p inserted into Xq21.3. FISH results for the mother were normal for both 1p and 9p probes. Late replication studies in the proband showed that random X-inactivation was occurring for the X

chromosome containing the 9p insertion (44% early replication, 56% late replication).

Following FISH analysis, G-banding was reviewed for the nine patients with subtelomeric aberrations. In all cases, the cytogenetic abnormality was still considered cryptic.

### DISCUSSION

Cryptic subtelomeric rearrangements have been shown to be a significant cause of unexplained mental retardation, and in the largest study to date Knight et al. [1999] found that almost half of their positive cases (10 out of 21) were familial. Of the 10 anomalies detected in the 9 positive cases of the current study, 5 were shown to be inherited, 3 were de novo, and 2 were unknown due to the unavailability of family members.

Patient 1 is the only abnormal case from the group of 53 patients with isolated idiopathic mental retardation/developmental delay. The del(22)(q13.33) of this patient encompassed most of the DNA to which the subtelomeric PAC99K24 hybridizes. The deletion was a de novo mutational event and the child's mental retardation and expressive speech delay are features commonly described in the 22q13.3 deletion syndrome [Phelan et al., 2001], although there can also be a range of less frequently described traits. Bonaglia et al.

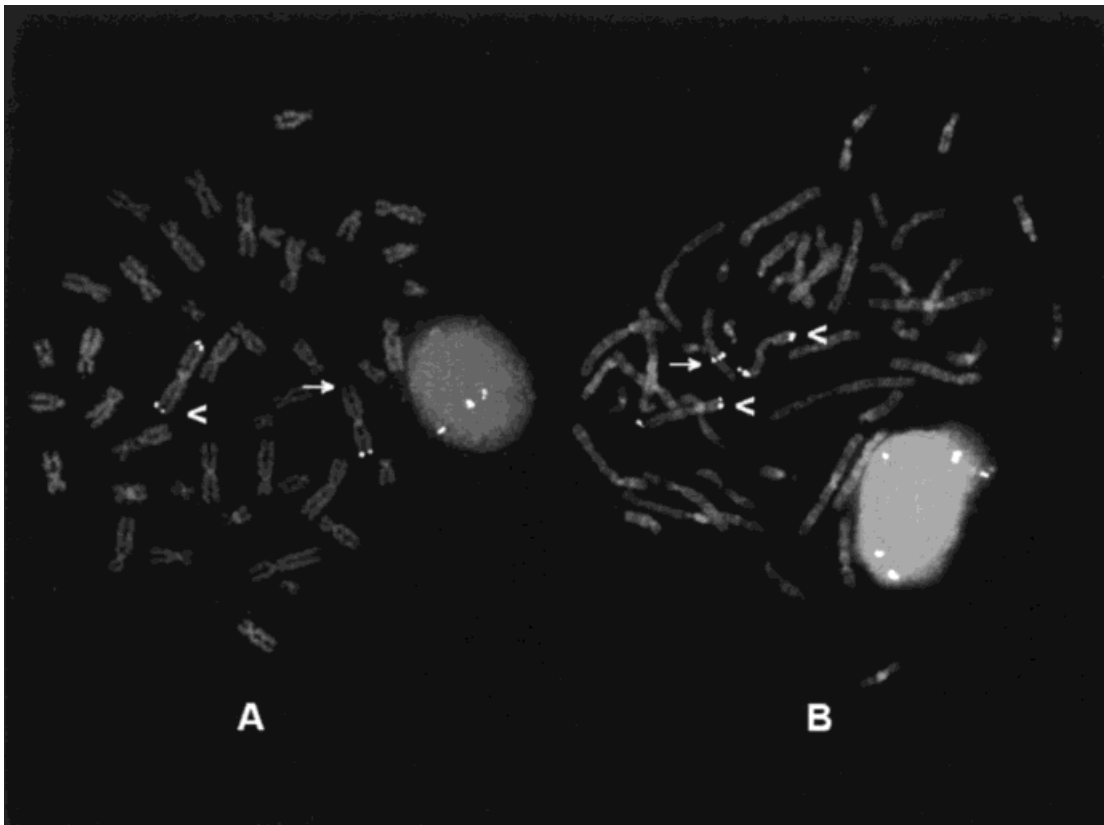


Fig. 3. Metaphases showing subtelomeric FISH to chromosomes from patient 9. **A:** Normal signal on one 1p (arrowhead) and no signal on the homolog (arrow) with PAC203K6. Signal from the 1q subtelomeric PAC160H23 is also present. **B:** Normal signal on both 9ps with PAC43N6 (arrowheads) and an extra 9p signal present at Xq21.3 (arrow). Signal from the 9q subtelomeric PAC112N13 is also present.

[2001] described a child with a de novo balanced translocation  $t(12;22)(q24.1;q13.3)$  and all the features of the 22q13.3 deletion syndrome. The chromosome 22 breakpoint lay within exon 21 of the human homolog of the rat ProSAP2 gene, a candidate gene for the 22q13.3 syndrome located in the 70 kb region of 22q between the distal ~60 kb of subtelomeric repeat-rich DNA and marker D22S163. The deletion breakpoint in patient 1 also lies within this region.

The remaining subtelomeric aberrations were found in patients whose mental retardation/developmental delay was associated with dysmorphic features and/or malformations. The rearrangement in patients 2 and 5 arose from the inheritance of a derivative chromosome from a parental balanced translocation, in patient 3 it arose from the de novo inheritance of a chromosome derived from a translocation, and in patient 6 a deleted chromosome was inherited from a parent with a similar deletion. The origins of the deletion in patient 4, and the deletion/duplication in patient 7, are unknown. The deletions and duplications in these six cases are sufficient to cause the phenotypes in the patients in whom they were found, and the results led to informative tests being carried out on a further 18 family members.

It is possible that one of the aberrations detected in this study is a rare and previously unreported polymorphism. This is the  $del(12p)$  in patient 8 and his mother. Studies to determine the size of the deletion have refined the breakpoint in the patient and his mother to a region 1.5–1.7 Mb from the telomere. This work is in progress. Terminal deletions of 12p are rare and carriers exhibit mild and variable phenotypes [Baroncini et al., 1990; Glass et al., 2000]. This may be the first detection of a cryptic subtelomeric abnormality of 12p.

Patient 9 presented an interesting problem of interpretation. Studies are underway to clarify the meaning of the extra 9p signal present in the child and her father. The de novo deletion of 1p present in the child was sufficient to account for her phenotype [Shapira et al., 1997], and the extra 9p signal may represent a rare and previously unreported cross-hybridization to a nontelomeric region, similar to the reported 11qter-12q interstitial and 22qter-2q interstitial cross-hybridizations [Knight et al., 1999]. It is also possible that both father and proband are trisomic for the most distal region of 9p, but that this has no clinical significance. A further possibility is that the extra 9p signal present at Xq21.3 represents a balanced insertion of part of 9pter into Xq. This would require the breakpoint on 9p to be well within the probe used in this study so that some of its homologous sequence remained on 9p and the remainder was inserted into Xq. In this case, there was a possibility that both father and proband were balanced carriers of the insertion, but that the female proband had preferential inactivation of the  $der(X)$  leading to an effective partial monosomy 9p. However, we have demonstrated that X-inactivation was random. A fourth possibility is that a balanced insertion in the father was inherited in unbalanced form by the proband leading to an effective partial trisomy 9p,

which has contributed in a minor way to the child's phenotype.

The set of probes described above produced a minimal number of cross-hybridizations/polymorphisms. The well-known polymorphism at 2q37.3 was present in only 4 of the 250 cases, appearing as a much lighter signal on one 2q. In no case was it completely undetectable. The two cross-hybridizations most commonly encountered were 8p-1p and 9q-18p. They were not difficult to assess as the usual appearance was minute secondary signals on both homologs of the cross-hybridizing chromosome pair.

Recently, a five-item clinical checklist was suggested by de Vries et al. [2001] as a means of improving the rate of detection of subtelomeric defects among mentally retarded individuals. All cases with subtelomeric rearrangements in that study had a score  $\geq 3$ . We have applied the checklist to our patients (Table I). Seven of the nine had scores  $\geq 3$  while two had scores of 2. For a diagnostic laboratory, the utility of the checklist is heavily dependent on the accuracy of the clinical details provided on the request form and, for this reason, we would be cautious about using it. The assessment of facial morphology is subjective and must take into account the parental phenotypes; patient 1 could have been described as dysmorphic but her mother had the same facial appearance and did not have the subtelomeric rearrangement. We also note that two of the criteria relate to a family history of mental retardation. For two of our patients with a family history compatible with Mendelian inheritance (patients 1 and 8), intellectual disability in at least one relative was not associated with the subtelomeric rearrangement. This does not negate the value of the criterion but highlights the difficulty in using it to select patients for testing.

Cryptic subtelomeric anomalies were found in 9 children out of a population of 250 with idiopathic mental retardation/developmental delay; 1/53 with isolated mental retardation/developmental delay (1.9%) and 8/197 with associated dysmorphic features and/or malformations (4.1%). The anomalies detected were diverse and the phenotypes of the affected individuals were as might be expected for small chromosome abnormalities in general. The severity of intellectual disability ranged from language disorder only to severe intellectual disability. Microcephaly, short stature, dysmorphic craniofacial features, and malformations frequently accompanied the intellectual disability. Caution is necessary in the interpretation of the significance of several of these subtelomeric abnormalities, as the full range of benign familial polymorphisms, or cross-hybridizations, has yet to be established. This study confirms the diagnostic utility of subtelomere FISH and suggests that the clinical criteria for requesting the test are similar to those that have been used in the past for requesting chromosome testing.

#### ACKNOWLEDGMENTS

This work was supported by the WCH Foundation, the APEX Foundation and the Wellcome Trust. The



authors thank the families who participated in the study, thereby making the data collection possible. We thank Dennis Romain, Trudy Hocking, Fiona Webb, and Mary Nicol for invaluable assistance during this project. We also thank the clinicians who referred the cases: D. Bratkovic, R. Couper, J. Dixon, C. Doocey, D. Ketteridge, B. Morris, C. Pridmore, M. Smiley, and G. Thompson.

## REFERENCES

- Anyon CP. 1965. Mental retardation and abnormal aminoacidurias occurring in a family. *NZ Med J* 64:3–6.
- Baroncini A, Avellini C, Neri C, Forabosco A. 1990. Distal 12p deletion in a stillborn infant. *Am J Med Genet* 36:358–360.
- Bonaglia MC, Giorda R, Borgatti R, Felisari G, Gagliardi C, Selicorni A, Zuffardi O. 2001. Disruption of the PreSAP2 gene in a t(12;22)(q24.1;q13.3) is associated with the 22q13.3 deletion syndrome. *Am J Hum Genet* 69:261–268.
- de Vries BBA, White SM, Knight SJJ, Regan R, Homfray T, Young ID, Super M, McKeown C, Splitt M, Quarrell OWJ, Trainer AH, Niermeijer MF, Malcolm S, Flint J, Hurst JA, Winter RM. 2001. Clinical studies on submicroscopic subtelomeric rearrangements: a checklist. *J Med Genet* 38:145–150.
- Flint J, Wilkie AOM, Buckle VJ, Winter RM, Holland AJ, McDermid HE. 1995. The detection of subtelomeric chromosomal rearrangements in idiopathic mental retardation. *Nat Genet* 9:132–139.
- Glass IA, Trenholme A, Mildenhall L, Bailey RJ, Cotter PD. 2000. Mild phenotype in two siblings with distal monosomy 12p13.31 → pter. *Clin Genet* 57:401–405.
- Jung R, Soondrum K, Neumaier M. 2000. Quantitative PCR. *Clin Chem Lab Med* 38:833–836.
- Knight SJJ, Flint J. 2000. Perfect endings: a review of subtelomeric probes and their use in clinical diagnosis. *J Med Genet* 37:401–409.
- Knight SJJ, Regan R, Nicod A, Horsley SW, Kearney L, Homfray T, Winter RM, Bolton P, Flint J. 1999. Subtle chromosomal rearrangements in children with unexplained mental retardation. *Lancet* 354:1676–1681.
- Knight SJJ, Lese CM, Precht KS, Kuc J, Ning Y, Lucas S, Regan R, Brenan M, Nicod A, Lawrie NM, Cardy DLN, Nguyen H, Hudson TJ, Riethman HC, Ledbetter DH, Flint J. 2000. An optimized set of human telomere clones for studying telomere integrity and architecture. *Am J Hum Genet* 67:320–332.
- National Institutes of Health and Institute of Molecular Medicine Collaboration. 1996. A complete set of human telomeric probes and their clinical application. *Nat Genet* 14:86–89.
- Phelan MC, Rogers RC, Saul RA, Stapleton GA, Sweet K, McDermid H, Shaw SR, Claytor J, Willis J, Kelly DP. 2001. 22q13 Deletion Syndrome. *Am J Med Genet* 101:91–99.
- Rao E, Weiss B, Fukami M, Rump A, Niesler B, Mertz A, Muroya K, Binder G, Kirsch S, Winkelmann M, Nordsiek G, Heinrich U, Breuning MH, Ranke MB, Rosenthal A, Ogata T, Rappold GA. 1997. Pseudoautosomal deletions encompassing a novel homeobox gene cause growth failure in idiopathic short stature and Turner syndrome. *Nature Genetics* 16:54–63.
- Reddy KS, Fugate JK. 1999. A half cryptic derivative der(18)t(5;18)pat identified by M-FISH and subtelomere probes: clinical findings and review of subtelomeric rearrangements. *Clin Genet* 56:328–332.
- Rossi E, Piccini F, Zollino M, Neri G, Caselli D, et al. 2001. Cryptic telomeric rearrangements in subjects with mental retardation associated with dysmorphism and congenital malformations. *J Med Genet* 38:417–420.
- Shapira SK, McCaskill C, Northrup H, Spikes AS, Elder FFB, Sutton VR, Korenberg JR, Greenberg F, Shaffer LG. 1997. Chromosome 1p36 deletions: the clinical phenotype and molecular characterization of a common newly delineated syndrome. *Am J Hum Genet* 61:642–650.
- Sismani C, Armour JAL, Flint J, Girgalli C, Regan R, Patsalis PC. 2001. Screening for subtelomeric chromosome abnormalities in children with idiopathic mental retardation using multiprobe telomeric FISH and the new MAPH telomeric assay. *Eur J Hum Genet* 9:527–532.
- Whitmore SA, Crawford J, Apostolou S, Eyre H, Baker E, Lower KM, Settasatian C, Goldup S, Seshadri R, Gibson RA, Mathew CG, Cleton-Jansen A-M, Savoia A, Pronk JC, Auerbach AD, Doggett NA, Sutherland GR, Callen DF. 1998. Construction of a high-resolution physical and transcription map of chromosome 16q24.3: a region of frequent loss of heterozygosity in sporadic breast cancer. *Genomics* 50:1–8.